A 65-year-old woman comes to the office to discuss pain at the posterior chest wall. She was seen 4 months ago for acute shingles involving a right mid-thoracic dermatome. The patient was not treated at that time because she had a delayed presentation and the lesions were already well-crusted and healing. The skin lesions subsequently cleared completely. However, since then, she has had persistent burning and stabbing pain in the same region that has now become severe. She has tried oral acetaminophen without relief. During discussion of treatment options, the patient says she does not want any systemic medications due to concerns about possible side effects. She is started on topical capsaicin cream, and her pain improves markedly over the next several days. Decreased activity of which of the following neurotransmitters is most likely associated with pain relief in this patient?

A. Acetylcholine
B. Dynorphin
C. Endorphin
D. Glycine
E. Histamine
F. Neuropeptide Y
G. Norepinephrine
H. Substance P

Submit

A 65-year-old woman comes to the office to discuss pain at the posterior chest wall. She was seen 4 months ago for acute shingles involving a right mid-thoracic dermatome. The patient was not treated at that time because she had a delayed presentation and the lesions were already well-crusted and healing. The skin lesions subsequently cleared completely. However, since then, she has had persistent burning and stabbing pain in the same region that has now become severe. She has tried oral acetaminophen without relief. During discussion of treatment options, the patient says she does not want any systemic medications due to concerns about possible side effects. She is started on topical capsaicin cream, and her pain improves markedly over the next several days. Decreased activity of which of the following neurotransmitters is most likely associated with pain relief in this patient?

- A. Acetylcholine (3%)
- B. Dynorphin (2%)
- C. Endorphin (2%)
- D. Glycine (1%)
- E. Histamine (1%)
- F. Neuropeptide Y (7%)
- G. Norepinephrine (0%)
- ✓ H. Substance P (79%)

Omitted
Correct answer
H

79%
Answered correctly

04 secs
Time Spent

02/05/2020
Last Updated

Explanation

Drugs for neuropathic pain

Drug	Mechanism of action
Tricyclic antidepressants (eg, amitriptyline, nortriptyline)	• ↓ Reuptake of serotonin & norepinephrine • Inhibition of pain signals
Anticonvulsants (eg, gabapentin, pregabalin)	• Decreased depolarization of neurons in CNS
Opioids	• Activation of central opioid receptors
Capsaicin (topical)	• Loss of membrane potential in nociceptive fibers
Lidocaine (topical)	• Decreased depolarization of neurons in peripheral nerves

CNS = central nervous system.

©UWorld

Shingles is due to reactivation of latent varicella zoster virus in sensory ganglia. It causes a vesicular rash and acute neuritis due to injury to the nerves. The initial pain fades within a few weeks to months, but a subset of patients will have residual neuropathic pain in the affected dermatome. This pain, termed **postherpetic neuralgia** (PHN), relates to sensitization of afferent nerves in the dorsal horn. It may last several months or longer, and has a burning, stabbing, or gnawing character. PHN is usually managed with tricyclic antidepressants (eg, amitriptyline) or

©UWorld

Shingles is due to reactivation of latent varicella zoster virus in sensory ganglia. It causes a vesicular rash and acute neuritis due to injury to the nerves. The initial pain fades within a few weeks to months, but a subset of patients will have residual neuropathic pain in the affected dermatome. This pain, termed **postherpetic neuralgia** (PHN), relates to sensitization of afferent nerves in the dorsal horn. It may last several months or longer, and has a burning, stabbing, or gnawing character. PHN is usually managed with tricyclic antidepressants (eg, amitriptyline) or anticonvulsants (eg, gabapentin, pregabalin), but nonsystemic options for PHN include lidocaine patches or topical capsaicin.

Capsaicin is an irritant found in the chili pepper family. It causes excessive activation of TRPV1 (a transmembrane cation channel), causing a buildup of intracellular calcium that results in long-lasting dysfunction of nociceptive nerve fibers (**defunctionalization**). In addition, capsaicin causes release and subsequent **depletion of substance P**, a polypeptide neurotransmitter involved in transmission of pain signals. On initial application, topical capsaicin causes burning, stinging, and erythema, but persistent exposure leads to a moderate reduction in pain over time.

(Choices A, D, E, and G) Capsaicin does not achieve its analgesic effect by acting on these neurotransmitters.

(Choices B and C) Endorphins and dynorphins are endogenous opioid peptides that achieve their pain-relieving effects by activating μ-opioid and κ-opioid receptors, respectively. Capsaicin does not affect the opioid system.

(Choice F) Neuropeptide Y (NPY) is a polypeptide neurotransmitter found in the central and autonomic nervous systems. It is thought to play a role in appetite and pain perception. NPY antagonists have been investigated as potential antiobesity drugs.

Educational objective:
Topical capsaicin causes defunctionalization of afferent pain fibers and depletion of substance P. Initial application results in a burning and stinging sensation, but chronic exposure leads to reduced pain transmission.

References

- Diagnosing and managing postherpetic neuralgia.
- Topical capsaicin for pain management: therapeutic potential and mechanisms of action of the new high-concentration capsaicin 8% patch.

Pharmacology	Nervous System	Capsaicin
Subject	System	Topic

©UWorld

Exhibit Display

Zoom In
Zoom Out
Reset
Add To New Card | Existing Card

A 62-year-old man comes to the emergency department due to right upper extremity weakness. Thirty minutes ago, the patient was at his office when he developed difficulty holding a pen. His grip in the right hand was weak and he could not lift his right arm. He tried calling his coworker but could not speak. The patient has never had similar symptoms before. He had no loss of consciousness, weakness of other extremities, vision abnormality, or headache. The symptoms resolved spontaneously by the time paramedics arrived. Medical history is significant for hypertension and a 30-pack-year smoking history. The patient is a defense attorney and recently took on a high-profile case. Temperature is 36.9 C (98.4 F), blood pressure is 140/84 mm Hg, pulse is 82/min and regular, and respirations are 14/min. Physical examination shows no extremity weakness or sensory loss. There is a left carotid bruit; the remainder of the examination shows no abnormalities. Noncontrast CT scan of the head is normal. Which of the following pharmacotherapies is most appropriate in management of this patient?

A. CNS-targeted immunomodulator

B. GABA A receptor modulator

C. HMG-CoA reductase inhibitor

D. Selective serotonin reuptake inhibitor

E. Tissue plasminogen activator

Submit

A 62-year-old man comes to the emergency department due to right upper extremity weakness. Thirty minutes ago, the patient was at his office when he developed difficulty holding a pen. His grip in the right hand was weak and he could not lift his right arm. He tried calling his coworker but could not speak. The patient has never had similar symptoms before. He had no loss of consciousness, weakness of other extremities, vision abnormality, or headache. The symptoms resolved spontaneously by the time paramedics arrived. Medical history is significant for hypertension and a 30-pack-year smoking history. The patient is a defense attorney and recently took on a high-profile case. Temperature is 36.9 C (98.4 F), blood pressure is 140/84 mm Hg, pulse is 82/min and regular, and respirations are 14/min. Physical examination shows no extremity weakness or sensory loss. There is a left carotid bruit; the remainder of the examination shows no abnormalities. Noncontrast CT scan of the head is normal. Which of the following pharmacotherapies is most appropriate in management of this patient?

A. CNS-targeted immunomodulator (1%)

B. GABA A receptor modulator (4%)

✓ C. HMG-CoA reductase inhibitor (54%)

D. Selective serotonin reuptake inhibitor (4%)

E. Tissue plasminogen activator (35%)

Omitted
Correct answer
C

54%
Answered correctly

01 sec
Time Spent

03/11/2020
Last Updated

Explanation

This patient with cardiovascular risk factors (ie, hypertension, smoking) and a carotid bruit developed right upper extremity weakness and aphasia that resolved without intervention; this is characteristic of a **transient ischemic attack** (TIA), which, in this case, likely occured

This patient with cardiovascular risk factors (ie, hypertension, smoking) and a carotid bruit developed right upper extremity weakness and aphasia that resolved without intervention; this is characteristic of a **transient ischemic attack** (TIA), which, in this case, likely occured following atheroembolization or low flow from the patient's carotid artery lesion. TIAs are defined as **focal neurologic deficits** that occur due to **transient brain ischemia**; tissue infarction does not occur, and brain imaging is normal. Symptoms are typically localized to a singular vascular territory and resolve without intervention, typically in <24 hours.

Patients with TIA are at markedly increased risk of future stroke; therefore, intensive medical management is indicated. Secondary prevention includes **antiplatelet agents** (eg, aspirin, clopidogrel) to prevent thrombus formation and **statin** therapy (**HMG-CoA reductase inhibitor**; eg, atorvastatin, rosuvastatin) to reduce atherosclerotic plaque formation. Lifestyle modifications (eg, exercise, tobacco cessation) are also recommended.

(Choice A) CNS-targeted immunomodulators (eg, ocrelizumab) or glucocorticoids are used in the treatment of multiple sclerosis (MS), a demyelinating disease that causes relapsing and remitting neurologic deficits. However, MS typically occurs in young women and neurologic deficits are slowly progressive over the course of days.

(Choice B) Benzodiazepines (GABA A receptor modulators) are used for acute seizure termination. Seizures can cause postictal paralysis but are typically preceded by stereotyped positive symptoms (eg, repetitive limb movement, lip smacking), whereas TIAs often typically cause negative symptoms (eg, loss of limb function, aphasia). In addition, seizure patients often have postictal confusion or sedation.

(Choice D) Selective serotonin reuptake inhibitors are used for treating anxiety or depression.

(Choice E) Tissue plasminogen activator ([TPA]; eg, alteplase) is used for thrombolysis in patients with acute, potentially debilitating, ischemic stroke, which would present with persistent neurologic deficits. TPA is not indicated as this patient's symptoms resolved without intervention.

Educational objective:
Transient ischemic attacks (TIAs) are transient episodes of focal neurologic impairment that occur due to local brain ischemia; tissue infarction does not occur, and brain imaging is normal. Patients with TIA are at increased risk of future stroke; secondary prevention includes antiplatelet agents (eg, aspirin, clopidogrel), statins, and lifestyle modifications (eg, tobacco cessation, exercise) to reduce future risk.

Pharmacology Nervous System Transient ischemic attack

A 26-year-old man with depressed mental status is brought to the emergency department by police. Due to fear of arrest, he swallowed a handful of pills as the officers approached him. On examination, the patient responds to painful stimuli but is somnolent. Respiratory rate is 6/min and after naloxone bolus infusion increases to 14/min. Lungs are clear to auscultation. Which of the following additional findings were most likely present in this patient on initial assessment?

A. Miosis, decreased bowel signs, hypertension

B. Miosis, decreased bowel signs, hypotension

C. Miosis, increased bowel signs, hypertension

D. Mydriasis, decreased bowel signs, hypotension

E. Mydriasis, increased bowel signs, hypertension

Submit

A 26-year-old man with depressed mental status is brought to the emergency department by police. Due to fear of arrest, he swallowed a handful of pills as the officers approached him. On examination, the patient responds to painful stimuli but is somnolent. Respiratory rate is 6/min and after naloxone bolus infusion increases to 14/min. Lungs are clear to auscultation. Which of the following additional findings were most likely present in this patient on initial assessment?

- A. Miosis, decreased bowel signs, hypertension (6%)
- ✓ B. Miosis, decreased bowel signs, hypotension (82%)
- C. Miosis, increased bowel signs, hypertension (3%)
- D. Mydriasis, decreased bowel signs, hypotension (7%)
- E. Mydriasis, increased bowel signs, hypertension (0%)

Omitted
Correct answer
B

82%
Answered correctly

03 secs
Time Spent

02/04/2020
Last Updated

Explanation

This patient developed somnolence and decreased respiratory rate after ingesting unknown pills during a confrontation with the police, which is suggestive of **opioid intoxication**. This is confirmed by improvement of the respiratory rate on administration of naloxone, an opioid antagonist. **Decreased respiratory rate** is the **best predictor** of opioid intoxication and is also a frequent cause of mortality.

In addition to depressed mental status and decreased respiratory rate, other classic indications of opioid intoxication include **miosis**, **decreased bowel signs**, and decreased tidal volume. **Hypotension** may also occur due to opioid-induced histamine release from mast cells.

(Choices A, C, D, and E) Opioid intoxication does not cause mydriasis, increased bowel signs, or hypertension. Mydriasis and hypertension can

Omitted
Correct answer
B

82%
Answered correctly

03 secs
Time Spent

02/04/2020
Last Updated

Explanation

This patient developed somnolence and decreased respiratory rate after ingesting unknown pills during a confrontation with the police, which is suggestive of **opioid intoxication**. This is confirmed by improvement of the respiratory rate on administration of naloxone, an opioid antagonist. **Decreased respiratory rate** is the **best predictor** of opioid intoxication and is also a frequent cause of mortality.

In addition to depressed mental status and decreased respiratory rate, other classic indications of opioid intoxication include **miosis**, **decreased bowel signs**, and decreased tidal volume. **Hypotension** may also occur due to opioid-induced histamine release from mast cells.

(Choices A, C, D, and E) Opioid intoxication does not cause mydriasis, increased bowel signs, or hypertension. Mydriasis and hypertension can result from cocaine or other stimulant intoxication.

Educational objective:
Opioid intoxication presents with miosis, depressed mental status, decreased respiratory rate, decreased bowel sounds, and hypotension. Of these, decreased respiratory rate is the best predictor of intoxication and is also a frequent cause of mortality.

References

- Drugs of abuse.
- Substance use, intoxication, and withdrawal in the critical care setting.
- Opioid use disorders.

Pharmacology	Nervous System	Opioids
Subject	System	Topic

Copyright © UWorld. All rights reserved.

A 42-year-old woman is hospitalized for surgical removal of a mediastinal mass. The patient has had intermittent episodes of double vision, difficulty chewing food, and weakness of the extremities for the past several months. During evaluation she was found to have a circumscribed anterior mediastinal mass. Preoperative nerve conduction studies revealed a decremental response to repetitive motor nerve stimulation. She has no other medical conditions and does not use tobacco, alcohol, or illicit drugs. The patient has no drug allergies. Compared to a healthy individual, which of the following anesthesia-related medications is most likely to have increased potency in this patient?

A. Isoflurane
B. Midazolam
C. Neostigmine
D. Atropine
E. Vecuronium

Submit

A 42-year-old woman is hospitalized for surgical removal of a mediastinal mass. The patient has had intermittent episodes of double vision, difficulty chewing food, and weakness of the extremities for the past several months. During evaluation she was found to have a circumscribed anterior mediastinal mass. Preoperative nerve conduction studies revealed a decremental response to repetitive motor nerve stimulation. She has no other medical conditions and does not use tobacco, alcohol, or illicit drugs. The patient has no drug allergies. Compared to a healthy individual, which of the following anesthesia-related medications is most likely to have increased potency in this patient?

A. Isoflurane (7%)
B. Midazolam (2%)
C. Neostigmine (27%)
D. Atropine (16%)
✓ E. Vecuronium (45%)

Omitted
Correct answer
E

45%
Answered correctly

01 sec
Time Spent

03/18/2020
Last Updated

Explanation

This patient has an anterior mediastinal mass and a nerve conduction study consistent with **myasthenia gravis** (MG), an autoimmune disease caused by **autoantibodies** against postsynaptic **nicotinic acetylcholine receptors** of the neuromuscular junction. Antibody-induced degradation leads to fewer functional receptors, which may be insufficient to generate muscle action potentials despite normal acetylcholine release. Weakness (most commonly of the extraocular, bulbar, and proximal muscles) worsens with repetitive nerve stimulation (**fatigability**) as acetylcholine stores in the presynaptic nerve terminal are depleted. **Thymic abnormalities** (eg, thymoma, thymic hyperplasia) are common and

This patient has an anterior mediastinal mass and a nerve conduction study consistent with **myasthenia gravis** (MG), an autoimmune disease caused by **autoantibodies** against postsynaptic **nicotinic acetylcholine receptors** of the neuromuscular junction. Antibody-induced degradation leads to fewer functional receptors, which may be insufficient to generate muscle action potentials despite normal acetylcholine release. Weakness (most commonly of the extraocular, bulbar, and proximal muscles) worsens with repetitive nerve stimulation (**fatigability**) as acetylcholine stores in the presynaptic nerve terminal are depleted. **Thymic abnormalities** (eg, thymoma, thymic hyperplasia) are common and may appear as an anterior mediastinal mass on imaging.

Neuromuscular blocking agents are used to induce skeletal muscle relaxation during surgery by competing with acetylcholine at the postsynaptic membrane. They can be subclassified by their effects:

- **Nondepolarizing agents** (eg, **vecuronium**, rocuronium) are **competitive antagonists** of nicotinic acetylcholine receptors. Due to the low number of functioning receptors, patients with MG are **extremely sensitive** to these agents; very small doses can induce paralysis with loss of airway patency.
- **Depolarizing agents** (eg, succinylcholine) are **competitive agonists** of nicotinic acetylcholine receptors; persistent depolarization leads to desensitization of the motor end plate. Due to the low number of functioning receptors, patients with MG are often **resistant** to these agents; extremely large doses are required to induce muscle relaxation.

(Choices A and B) Isoflurane is a general anesthetic (acts centrally on multiple receptors) that can cause malignant hyperthermia in those with genetic predispositions. Midazolam is a benzodiazepine (acts on the $GABA_A$ receptor) to produce sedation. These medications are not contraindicated in MG.

(Choice C) The mainstay of symptomatic treatment for MG is acetylcholinesterase inhibitors (eg, pyridostigmine, neostigmine); these agents inhibit the degradation of acetylcholine in the synapse, thereby increasing the amount available to stimulate muscle contractions.

(Choice D) Atropine is a muscarinic acetylcholine receptor antagonist often used as premedication before general anesthesia to decrease salivary and bronchial secretions (helps maintain airway patency) and prevent myocardial depression (minimizes risk of hypotension); it has no effect on nicotinic acetylcholine receptors in the neuromuscular junctions.

Educational objective:
Myasthenia gravis (MG) is caused by autoantibodies against postsynaptic nicotinic acetylcholine receptors, leading to fewer functional receptors and fatigable muscle weakness. Nondepolarizing neuromuscular blocking agents (eg, vecuronium) are competitive antagonists of nicotinic

This patient has an anterior mediastinal mass and a nerve conduction study consistent with **myasthenia gravis** (MG), an autoimmune disease

Exhibit Display

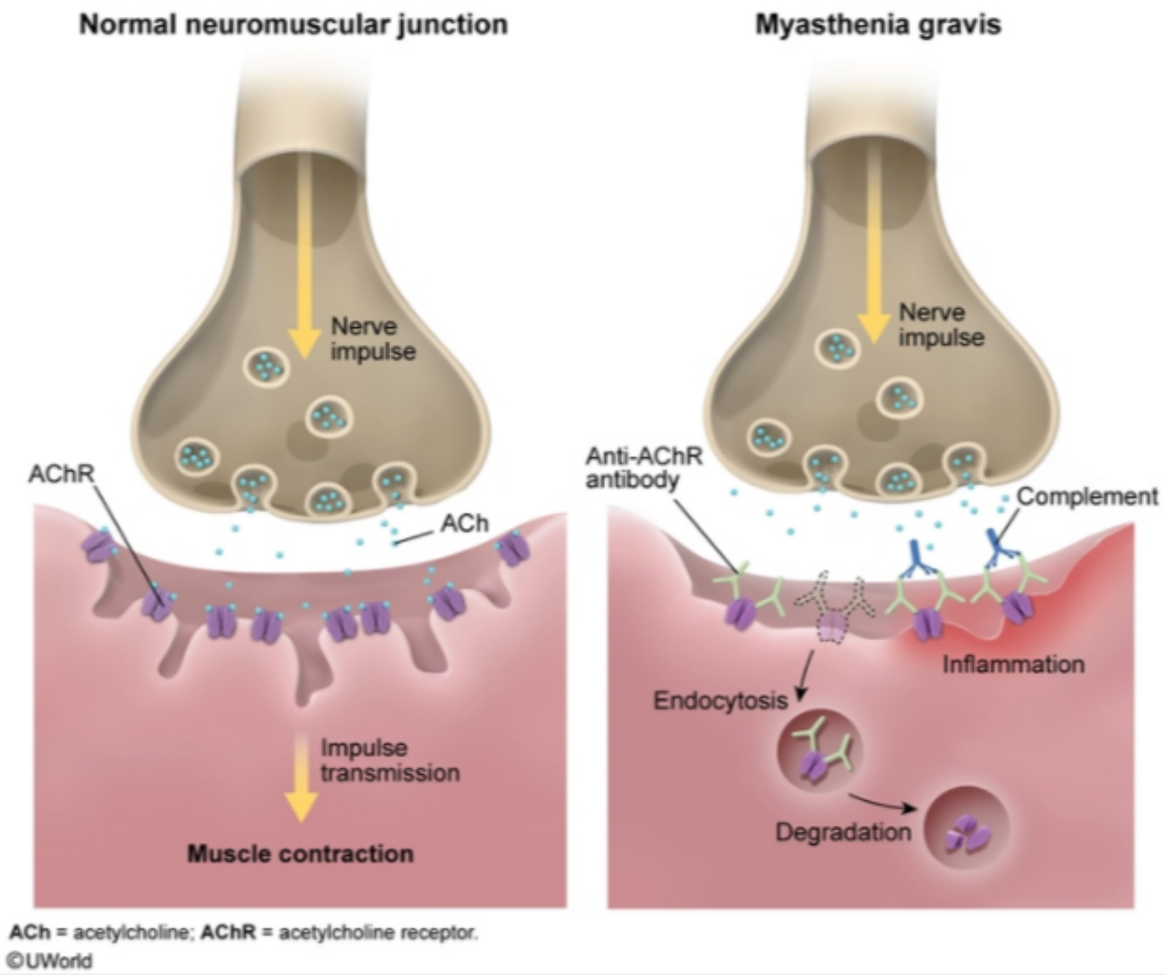

ACh = acetylcholine; **AChR** = acetylcholine receptor.
©UWorld

Zoom In | Zoom Out | Reset | Add To New Card | Existing Card

and fatigable muscle weakness. Nondepolarizing neuromuscular blocking agents (eg, vecuronium) are competitive antagonists of nicotinic

Neuromuscular blocking agents are used to induce skeletal muscle relaxation during surgery by competing with acetylcholine at the postsynaptic membrane. They can be subclassified by their effects:

- **Nondepolarizing agents** (eg, **vecuronium**, rocuronium) are **competitive antagonists** of nicotinic acetylcholine receptors. Due to the low number of functioning receptors, patients with MG are **extremely sensitive** to these agents; very small doses can induce paralysis with loss of airway patency.
- **Depolarizing agents** (eg, succinylcholine) are **competitive agonists** of nicotinic acetylcholine receptors; persistent depolarization leads to desensitization of the motor end plate. Due to the low number of functioning receptors, patients with MG are often **resistant** to these agents; extremely large doses are required to induce muscle relaxation.

(Choices A and B) Isoflurane is a general anesthetic (acts centrally on multiple receptors) that can cause malignant hyperthermia in those with genetic predispositions. Midazolam is a benzodiazepine (acts on the $GABA_A$ receptor) to produce sedation. These medications are not contraindicated in MG.

(Choice C) The mainstay of symptomatic treatment for MG is acetylcholinesterase inhibitors (eg, pyridostigmine, neostigmine); these agents inhibit the degradation of acetylcholine in the synapse, thereby increasing the amount available to stimulate muscle contractions.

(Choice D) Atropine is a muscarinic acetylcholine receptor antagonist often used as premedication before general anesthesia to decrease salivary and bronchial secretions (helps maintain airway patency) and prevent myocardial depression (minimizes risk of hypotension); it has no effect on nicotinic acetylcholine receptors in the neuromuscular junctions.

Educational objective:
Myasthenia gravis (MG) is caused by autoantibodies against postsynaptic nicotinic acetylcholine receptors, leading to fewer functional receptors and fatigable muscle weakness. Nondepolarizing neuromuscular blocking agents (eg, vecuronium) are competitive antagonists of nicotinic receptors; due to the depletion of receptors, patients with MG are extremely sensitive to these agents.

Pharmacology	Nervous System	Myasthenia gravis
Subject	System	Topic

Copyright © UWorld. All rights reserved.

A 65-year-old male is undergoing rehabilitation after a stroke. Ten days ago, he presented to the emergency department with abrupt onset of left upper and lower extremity weakness. He has a history of hypertension, hypercholesterolemia, gastroesophageal reflux disease and hypothyroidism. He does not use tobacco, alcohol or illicit drugs. His blood pressure is 140/90 mm Hg and pulse is 72/min. He has weakness and increased tone in the left upper and lower extremities. You prescribe diazepam to this patient in order to decrease muscle spasticity of involved extremities. This patient should primarily be cautioned to avoid which of the following drugs?

- A. Chlorpheniramine
- B. Loratadine
- C. Acetaminophen
- D. Ranitidine
- E. Lansoprazole
- F. Folic acid

Submit

A 65-year-old male is undergoing rehabilitation after a stroke. Ten days ago, he presented to the emergency department with abrupt onset of left upper and lower extremity weakness. He has a history of hypertension, hypercholesterolemia, gastroesophageal reflux disease and hypothyroidism. He does not use tobacco, alcohol or illicit drugs. His blood pressure is 140/90 mm Hg and pulse is 72/min. He has weakness and increased tone in the left upper and lower extremities. You prescribe diazepam to this patient in order to decrease muscle spasticity of involved extremities. This patient should primarily be cautioned to avoid which of the following drugs?

- ✓ A. Chlorpheniramine (43%)
- B. Loratadine (9%)
- C. Acetaminophen (12%)
- D. Ranitidine (19%)
- E. Lansoprazole (14%)
- F. Folic acid (1%)

Omitted
Correct answer
A

43%
Answered correctly

01 sec
Time Spent

02/05/2020
Last Updated

Explanation

Diazepam is a long-acting benzodiazepine indicated as follows:

1. As an **anxiolytic**, it is effective for the management of generalized anxiety disorder and panic attacks.
2. The **sedative-hypnotic** effect of diazepam is useful for the short-term treatment of insomnia

Diazepam is a long-acting benzodiazepine indicated as follows:

1. As an **anxiolytic**, it is effective for the management of generalized anxiety disorder and panic attacks.
2. The **sedative-hypnotic** effect of diazepam is useful for the short-term treatment of insomnia.
3. As an **anticonvulsant**, diazepam is indicated for status epilepticus. It is a first-line agent (along with chlordiazepoxide) for the treatment of seizures associated with alcohol withdrawal.
4. As a **muscle relaxant**, diazepam can stop the spasticity caused by upper motor neuron disorders (multiple sclerosis, strokes, spinal cord trauma) and tetanus.

The most common side effect of diazepam is sedation. Diazepam may also impair coordination and balance (sometimes avoided in the elderly for fear of falls), decrease memory and concentration, and produce confusion. These effects are amplified by the co-administration of other CNS-depressants. As a class, all benzodiazepines should be excluded from use in conjunction with alcohol, barbiturates, neuroleptics, or 1st generation antihistamines.

Among drugs listed in the answer choices, only chlorpheniramine causes sedation and should not be used with diazepam. Chlorpheniramine is a 1st generation antihistamine that acts by blocking both central and peripheral H1 receptors. Chlorpheniramine and other 1st generation antihistamines can be very sedating because they easily penetrate the blood-brain barrier and accumulate in the CNS. The most sedating of this generation of antihistamines are diphenhydramine (Benadryl), promethazine, and hydroxyzine. Despite the associated sedation, these antihistamines are often still used to prevent/treat allergic reactions and motion sickness and as antiemetics.

(Choice B) Loratadine is a second-generation antihistamine that blocks peripheral H1 histamine receptors. It does not enter the CNS and does not cause drowsiness.

(Choice D) Ranitidine is a H2 receptor antagonist that inhibits gastric acid secretion. It has a slight affinity to the CYP450 enzyme, but studies have shown that ranitidine does not have clinically significant interactions with diazepam.

(Choice E) Lansoprazole is a proton pump inhibitor that decreases gastric acid secretion. Although both diazepam and lansoprazole are metabolized by the P450 system, studies have shown that lansoprazole does not have clinically significant interactions with diazepam.

Educational objective:
First generation H1-histamine receptor antagonists, including diphenhydramine and chlorpheniramine, can cause significant sedation, especially

depressants. As a class, all benzodiazepines should be excluded from use in conjunction with alcohol, barbiturates, neuroleptics, or 1st generation antihistamines.

Among drugs listed in the answer choices, only chlorpheniramine causes sedation and should not be used with diazepam. Chlorpheniramine is a 1st generation antihistamine that acts by blocking both central and peripheral H1 receptors. Chlorpheniramine and other 1st generation antihistamines can be very sedating because they easily penetrate the blood-brain barrier and accumulate in the CNS. The most sedating of this generation of antihistamines are diphenhydramine (Benadryl), promethazine, and hydroxyzine. Despite the associated sedation, these antihistamines are often still used to prevent/treat allergic reactions and motion sickness and as antiemetics.

(Choice B) Loratadine is a second-generation antihistamine that blocks peripheral H1 histamine receptors. It does not enter the CNS and does not cause drowsiness.

(Choice D) Ranitidine is a H2 receptor antagonist that inhibits gastric acid secretion. It has a slight affinity to the CYP450 enzyme, but studies have shown that ranitidine does not have clinically significant interactions with diazepam.

(Choice E) Lansoprazole is a proton pump inhibitor that decreases gastric acid secretion. Although both diazepam and lansoprazole are metabolized by the P450 system, studies have shown that lansoprazole does not have clinically significant interactions with diazepam.

Educational objective:
First generation H1-histamine receptor antagonists, including diphenhydramine and chlorpheniramine, can cause significant sedation, especially when used with other medications that cause CNS depression (such as benzodiazepines).

References

- Influence of lansoprazole treatment on diazepam plasma concentrations
- Ranitidine does not impair oxidative or conjugative metabolism: noninteraction with antipyrine, diazepam, and lorazepam

Pharmacology	Nervous System	Benzodiazepines
Subject	System	Topic

Copyright © UWorld. All rights reserved.

A 55-year-old man comes to the office due to intermittent shortness of breath, cough, and chest tightness over the past 3 months. The patient had asthma as a child that improved in adolescence, and he has not required inhalers or steroids since. He feels that his current symptoms are similar to his prior asthma symptoms. The patient was recently diagnosed with essential tremor, which has improved with medical therapy; he has no other chronic medical conditions. He is a lifetime nonsmoker and does not use alcohol or illicit drugs. Blood pressure is 125/75 mm Hg, pulse is 58/min, and respirations are 16/min. Physical examination reveals bilateral scattered expiratory wheezes. Heart sounds are normal and there is no extremity edema. This patient's symptom recurrence is most likely attributable to a medication that affects which of the following steps?

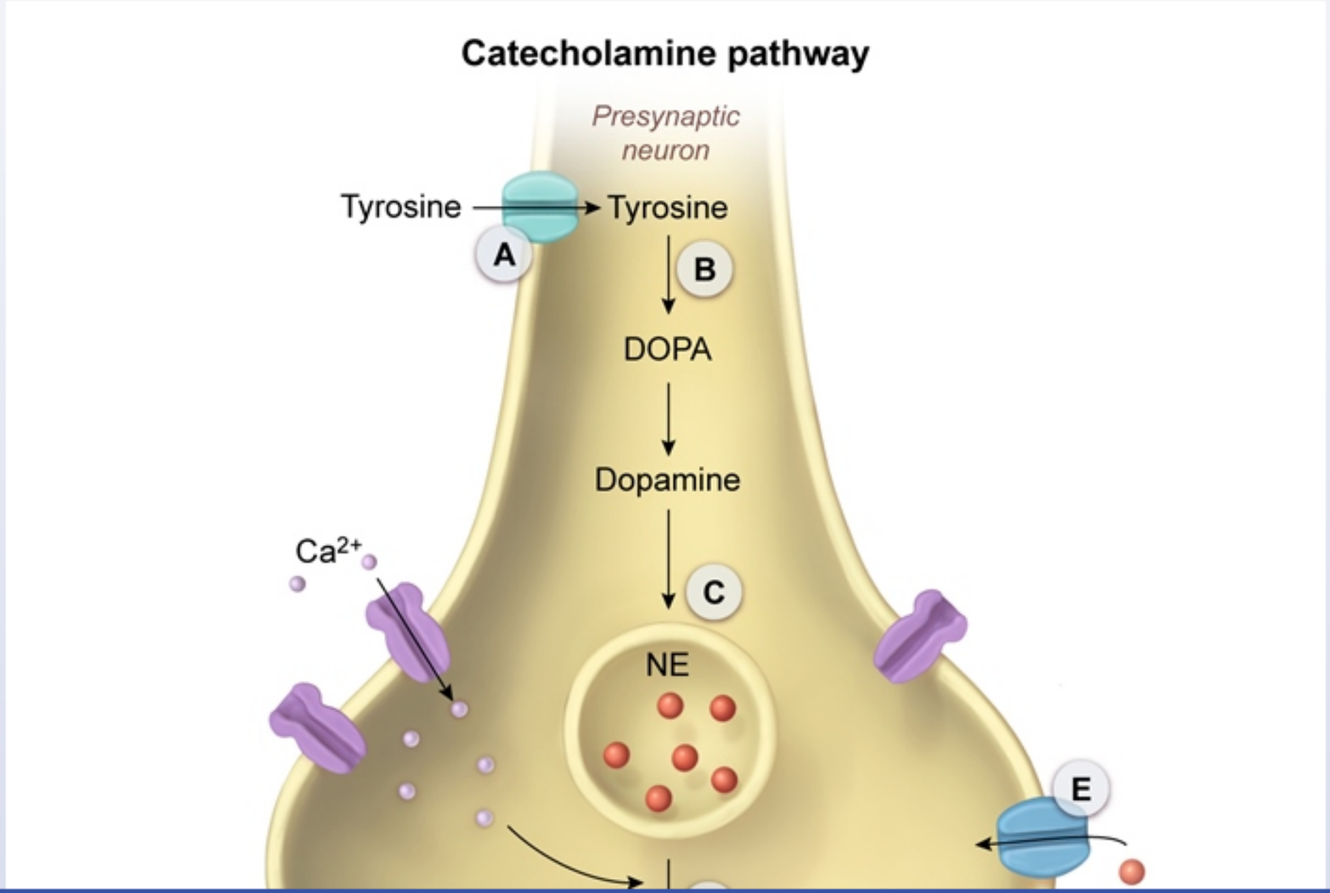

1
2
3
4
5
6
7
8
9
10
11
12
13
14
15
16
17
18
19
20
21
22

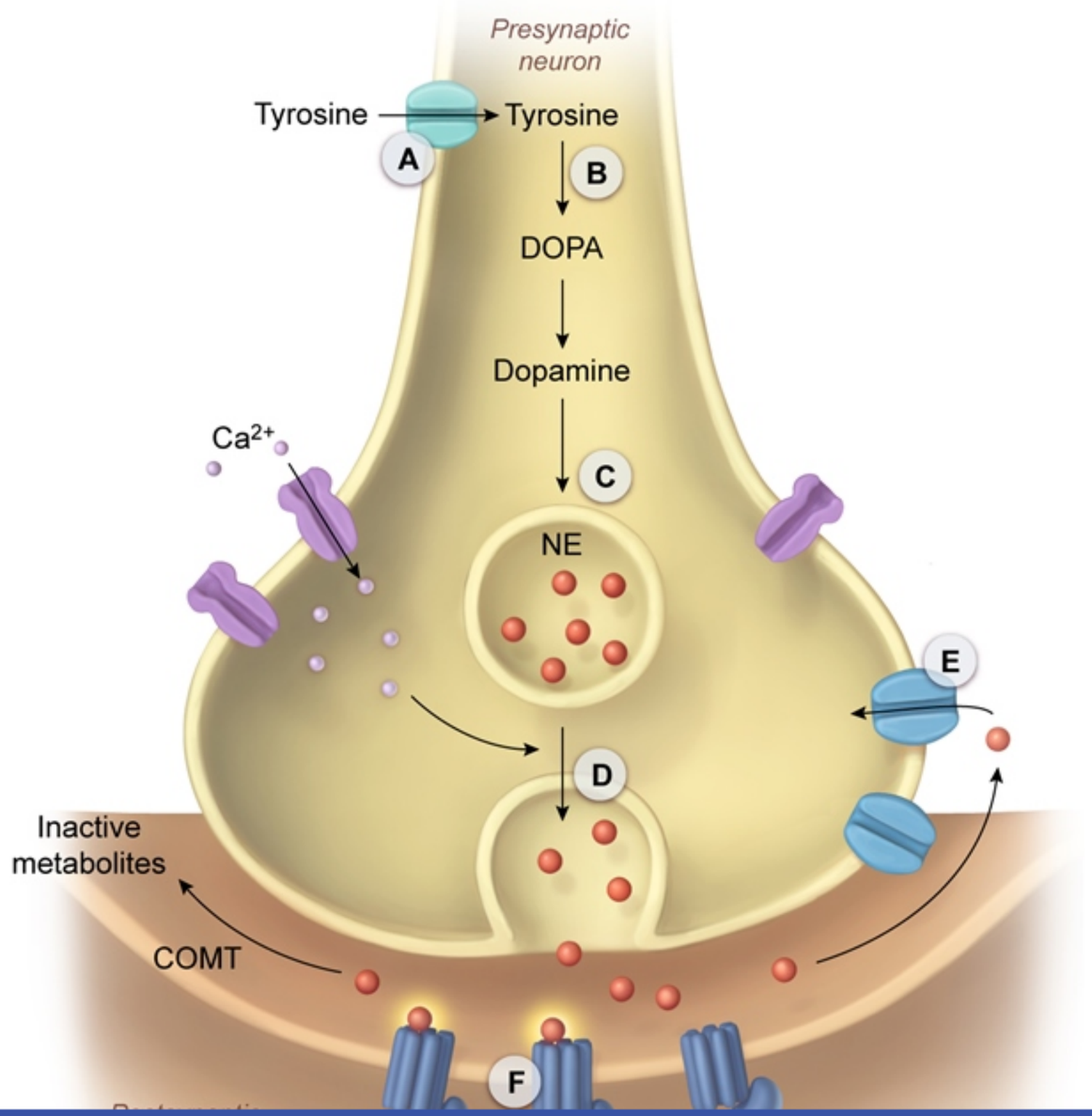

1
2
3
4
5
6
7
8
9
10
11
12
13
14
15
16
17
18
19
20
21
22

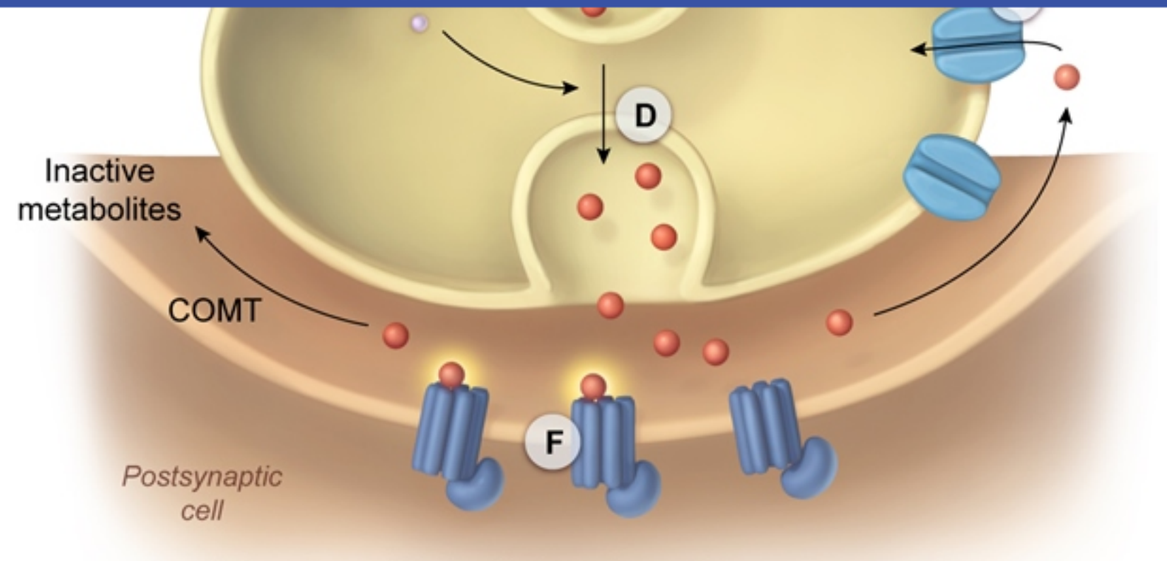

COMT = catechol-O-methyl transferase; **DOPA** = dihydroxyphenalanine.

©UWorld

A. A

B. B

C. C

D. D

E. E

F. F

Submit

1
2
3
4
5
6
7
8
9
10
11
12
13
14
15
16
17
18
19
20
21
22

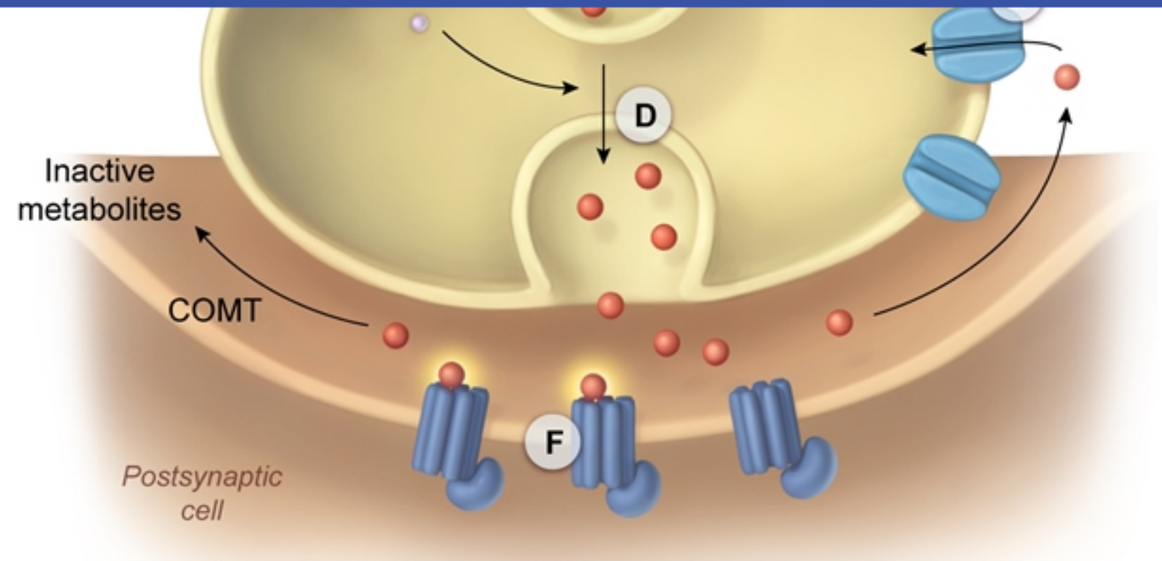

COMT = catechol-O-methyl transferase; **DOPA** = dihydroxyphenalanine.
©UWorld

A. A (1%)
B. B (4%)
C. C (7%)
D. D (13%)
E. E (19%)
✓ F. F (53%)

Omitted
Correct answer

53%
Answered correctly

07 secs
Time Spent

02/16/2020
Last Updated

Effects of adrenergic blockade			
Receptor	**Target organ**	**Effect**	**Potential adverse effects**
B1-adrenergic blockade	Heart	↓ Heart rate ↓ Contractility ↓ O_2 consumption	Worsening of heart failure Bradycardia/heart block
	Kidney	↓ Renin release	
B2-adrenergic blockade	Muscle vasculature	Vasospasm	Exacerbation of peripheral artery disease
	Lungs	Bronchoconstriction	Worsening of obstructive lung disease
	Liver	↓ Glycogenolysis & gluconeogenesis	May cause hypoglycemia in diabetic patients
	Most tissues	↓ Potassium entry into cells	Hyperkalemia

This patient has developed symptoms of intermittent asthma (eg, cough, wheeze, dyspnea) associated with a new medication for his **essential tremor** (ET). ET is a common movement disorder, and beta blockers are often used as first-line therapy for debilitating or distressful symptoms. Beta blockers prevent the interaction of epinephrine and norepinephrine with receptors at adrenergic synapses; in ET, this is thought to help dampen the sensitivity of muscle spindles, which improves tremor symptoms by smoothing out the force of contraction.

Propranolol, the most commonly used medication for treatment of ET, is a **nonselective beta blocker** (ie, inhibits both beta-1 and beta-2 receptors). In patients with reactive airway diseases (eg, asthma, chronic obstructive pulmonary disease), **inhibition of beta-2 receptors** can cause **bronchoconstriction** with resultant asthma symptoms. Selective beta-1 blockers are often better tolerated in patients with asthma; however, selectivity is dose-dependent and patients can develop bronchoconstriction at high doses.

(Choice A) Tyrosine is transported into the cell by the large neutral amino acid transporter.

(Choice B) The conversion of tyrosine to dihydroxyphenylalanine (DOPA) by tyrosine hydroxylase is the rate-limiting step in catecholamine biosynthesis. This enzyme was previously inhibited by drugs used to treat pheochromocytoma, but these are no longer used due to a poor side

dampen the sensitivity of muscle spindles, which improves tremor symptoms by smoothing out the force of contraction.

Propranolol, the most commonly used medication for treatment of ET, is a **nonselective beta blocker** (ie, inhibits both beta-1 and beta-2 receptors). In patients with reactive airway diseases (eg, asthma, chronic obstructive pulmonary disease), **inhibition of beta-2 receptors** can cause **bronchoconstriction** with resultant asthma symptoms. Selective beta-1 blockers are often better tolerated in patients with asthma; however, selectivity is dose-dependent and patients can develop bronchoconstriction at high doses.

(Choice A) Tyrosine is transported into the cell by the large neutral amino acid transporter.

(Choice B) The conversion of tyrosine to dihydroxyphenylalanine (DOPA) by tyrosine hydroxylase is the rate-limiting step in catecholamine biosynthesis. This enzyme was previously inhibited by drugs used to treat pheochromocytoma, but these are no longer used due to a poor side effect profile.

(Choice C) The medication reserpine inhibits vesicular monoamine transporter, thereby inhibiting dopamine entry into presynaptic vesicles and essentially causing a chemical sympathectomy. Reserpine is occasionally used as an antipsychotic. It may cause wheezing in some patients but is not indicated in the treatment of ET.

(Choice D) Adrenergic neuron blockers such as guanethidine inhibit norepinephrine release, lowering blood pressure and heart rate. Guanethidine is occasionally used for chronic pain syndrome but does not cause bronchoconstriction; it is not used in management of ET.

(Choice E) Tricyclic antidepressants and cocaine work by inhibiting norepinephrine reuptake by presynaptic neurons. These agents can worsen symptoms in ET.

Educational objective:
Beta blockers are used in the treatment of essential tremor. Propranolol, a nonselective beta blocker, is the most commonly used therapy and prevents the interaction of epinephrine and norepinephrine with beta-1 and beta-2 receptors to relieve tremor symptoms. However, inhibition of pulmonary beta-2 receptors in patients with underlying reactive airway disease can cause bronchoconstriction, leading to cough, wheeze, and dyspnea.

Pharmacology	Nervous System	Beta blockers
Subject	System	Topic

Copyright © UWorld. All rights reserved.

An 8-year-old boy is brought to the office by his mother for a routine checkup. He was diagnosed with absence seizures a year ago and has been undergoing treatment with an appropriate antiepileptic agent. The mother says that the patient is doing well and has not had any seizures since starting the medication. His school performance has improved significantly, and he no longer gets in trouble for "staring off" in class. He eats a well-balanced diet and is at the 50th percentile for height and weight. Which of the following is the most likely mechanism of action of the medication used in this patient?

A. Binds to GABA receptors and increases the chloride current

B. Binds to synaptic vesicles to modulate neurotransmitter release

C. Decreases the calcium current in thalamic neurons

D. Decreases the sodium current in cortical neurons

E. Increases brain beta-hydroxybutyrate acid levels

Submit

An 8-year-old boy is brought to the office by his mother for a routine checkup. He was diagnosed with absence seizures a year ago and has been undergoing treatment with an appropriate antiepileptic agent. The mother says that the patient is doing well and has not had any seizures since starting the medication. His school performance has improved significantly, and he no longer gets in trouble for "staring off" in class. He eats a well-balanced diet and is at the 50th percentile for height and weight. Which of the following is the most likely mechanism of action of the medication used in this patient?

A. Binds to GABA receptors and increases the chloride current (10%)

B. Binds to synaptic vesicles to modulate neurotransmitter release (4%)

✓ C. Decreases the calcium current in thalamic neurons (67%)

D. Decreases the sodium current in cortical neurons (16%)

E. Increases brain beta-hydroxybutyrate acid levels (1%)

Omitted
Correct answer
C

67%
Answered correctly

01 sec
Time Spent

04/03/2020
Last Updated

Explanation

Mechanisms of common antiseizure drugs	
Phenytoin	Blocks Na^+ channels
Carbamazepine	

Mechanisms of common antiseizure drugs	
Phenytoin	Blocks Na^+ channels
Carbamazepine	
Valproic acid	Blocks Na^+ channels & ↑ GABA levels
Benzodiazepine	↑ $GABA_A$ action
Phenobarbital	
Levetiracetam	Modulates GABA & glutamate release
Ethosuximide	Blocks thalamic T-type Ca^{2+} channels

Ethosuximide is the first-line treatment for **absence seizures**. This drug **blocks T-type Ca^{2+} channels** that trigger and sustain rhythmical burst discharges in **thalamic neurons**. Side effects of this drug are minimal and include nausea, vomiting, fatigue, and hyperactivity. If ethosuximide is not tolerated due to these side effects, or if the drug is ineffective in suppressing seizure activity, valproic acid is used as a second-line treatment for absence epilepsy. Valproic acid is a broad-spectrum antiseizure drug that inhibits voltage-dependent Na^+ channels and also causes a rise in GABA concentration.

(Choice A) Benzodiazepines and barbiturates (eg, phenobarbital) bind to GABA receptors and allow an increased chloride current through the ion channel. This hyperpolarizes the cell membrane, which increases the threshold of excitability of the postsynaptic neuron.

(Choice B) Levetiracetam binds to a synaptic vesicle protein (SV2A) to modulate the release of GABA and glutamate neurotransmitters.

(Choice D) Phenytoin decreases the sodium current in cortical neurons by reducing the ability of sodium channels to recover from inactivation. This increases the refractory period of the neuron, inhibiting neuronal high-frequency firing. Carbamazepine and valproic acid have similar mechanisms of action.

(Choice E) Increasing the levels of brain beta-hydroxybutyrate acid (ketone bodies) is the goal of the ketogenic diet. This high-fat, low-carbohydrate diet may benefit some patients with refractory epilepsy.

A 32-year-old woman comes to the emergency department due to severe headache, nausea, and vomiting for the past several hours. The headache is pounding and localized to the left side. She also describes bright spots in her vision prior to headache onset. The patient has had similar episodes occasionally since adolescence. Physical examination shows normal pupils and fundi, but the patient has discomfort to bright light. There is no facial droop, extremity weakness, or sensory loss. The patient is treated with metoclopramide and diphenhydramine. Which of the following is the most likely reason diphenhydramine was used in this patient?

A. To decrease the risk of arrhythmia

B. To increase the prokinetic effect

C. To prevent abnormal motor reaction

D. To prevent allergic reaction

E. To prevent rebound headache

Submit

A 32-year-old woman comes to the emergency department due to severe headache, nausea, and vomiting for the past several hours. The headache is pounding and localized to the left side. She also describes bright spots in her vision prior to headache onset. The patient has had similar episodes occasionally since adolescence. Physical examination shows normal pupils and fundi, but the patient has discomfort to bright light. There is no facial droop, extremity weakness, or sensory loss. The patient is treated with metoclopramide and diphenhydramine. Which of the following is the most likely reason diphenhydramine was used in this patient?

- A. To decrease the risk of arrhythmia (2%)
- B. To increase the prokinetic effect (11%)
- ✓ C. To prevent abnormal motor reaction (47%)
- D. To prevent allergic reaction (12%)
- E. To prevent rebound headache (26%)

Omitted
Correct answer
C

47%
Answered correctly

02 secs
Time Spent

05/02/2020
Last Updated

Explanation

Common antiemetic drugs			
Drug class	**Examples**	**Clinical uses**	**Major side effects**
Antimuscarinics (anticholinergics)	• Scopolamine	• Vestibular nausea	• Anticholinergic effects (eg, dry mouth,

Explanation

Common antiemetic drugs			
Drug class	**Examples**	**Clinical uses**	**Major side effects**
Antimuscarinics (anticholinergics)	• Scopolamine	• Vestibular nausea • Motion sickness	• Anticholinergic effects (eg, dry mouth, sedation)
Antihistamines	• Meclizine		
Dopamine receptor antagonists (DRAs)	• Prochlorperazine • Metoclopramide • Chlorpromazine	• Migraine headache (DRAs) • Acute or chronic nausea/vomiting • Acute chemotherapy-induced emesis	• Extrapyramidal reactions
Serotonin (5-HT_3) receptor antagonists	• Ondansetron • Granisetron		• QT prolongation
Neurokinin-1 (NK1) receptor antagonists	• Aprepitant • Fosaprepitant	• Delayed chemotherapy-induced emesis	• Neutropenia

This patient with a normal neurologic examination has unilateral headache associated with **nausea and vomiting**, photophobia, and a visual aura (eg, flashing lights), features that are consistent with **migraine headache**.

Severe migraine headache with nausea and vomiting is typically treated with a serotonin 1B/1D agonist (ie, triptans) or a **dopamine receptor blocker** (eg, metoclopramide, prochlorperazine) to abort the migraine and treat associated nausea and vomiting. Dopamine receptor blockers have both antiemetic and analgesic effects on migraine headaches by antagonizing central dopamine **D2 receptors** in the midbrain and striatum.

Dopamine receptor blockade in the basal ganglia can also cause **excess cholinergic activity** that manifests as significant **extrapyramidal symptoms**, such as **acute dystonic reaction** (eg, torticollis, oculogyric crisis). Therefore, **diphenhydramine** can be co-administered with metoclopramide or prochlorperazine to prevent such reactions due to its **anticholinergic activity**.

(Choice A) The 5HT_3 receptor antagonists ondansetron and granisetron have a low risk of QT prolongation leading to torsade de pointes

This patient with a normal neurologic examination has unilateral headache associated with **nausea and vomiting**, photophobia, and a visual aura (eg, flashing lights), features that are consistent with **migraine headache**.

Severe migraine headache with nausea and vomiting is typically treated with a serotonin 1B/1D agonist (ie, triptans) or a **dopamine receptor blocker** (eg, metoclopramide, prochlorperazine) to abort the migraine and treat associated nausea and vomiting. Dopamine receptor blockers have both antiemetic and analgesic effects on migraine headaches by antagonizing central dopamine **D2 receptors** in the midbrain and striatum.

Dopamine receptor blockade in the basal ganglia can also cause **excess cholinergic activity** that manifests as significant **extrapyramidal symptoms**, such as **acute dystonic reaction** (eg, torticollis, oculogyric crisis). Therefore, **diphenhydramine** can be co-administered with metoclopramide or prochlorperazine to prevent such reactions due to its **anticholinergic activity**.

(Choice A) The $5HT_3$ receptor antagonists ondansetron and granisetron have a low risk of QT prolongation leading to torsade de pointes. However, administration of diphenhydramine does not decrease this risk.

(Choice B) Metoclopramide has prokinetic activity (eg, enhances gastric emptying) and can be useful in the treatment of nausea and vomiting associated with diabetic gastroparesis. However, administration of diphenhydramine would decrease this prokinetic effect due to its anticholinergic activity (eg, reduced gut motility).

(Choice D) Diphenhydramine is a first-generation (H1) antihistamine used to treat urticaria, which can occur with allergic drug reactions. However, it is not used to prevent occurrence of allergic reactions.

(Choice E) Rebound headache can occur with excessive use (eg, >10 days a month) of certain abortive migraine medications (eg, triptans, analgesics). Dopamine receptor antagonists are not typically associated with rebound headache.

Educational objective:
Dopamine receptor blockers (eg, metoclopramide, prochlorperazine) act as antiemetics and pain relievers for severe migraine headache associated with nausea and vomiting. However, dopamine blockade can also result in excess cholinergic activity (eg, acute dystonic reactions); diphenhydramine can be co-administered with dopamine receptor blockers to prevent these reactions due to its anticholinergic activity.

References

- Migraine treatment: current acute medications and their potential mechanisms of action.

1
2
3
4
5
6
7
8
9
10
11
12
13
14
15
16
17
18
19
20
21
22

This patient with a normal neurologic examination has unilateral headache associated with **nausea and vomiting**, photophobia, and a visual aura.

Exhibit Display

Migraine pathogenesis & triptan mechanism of action

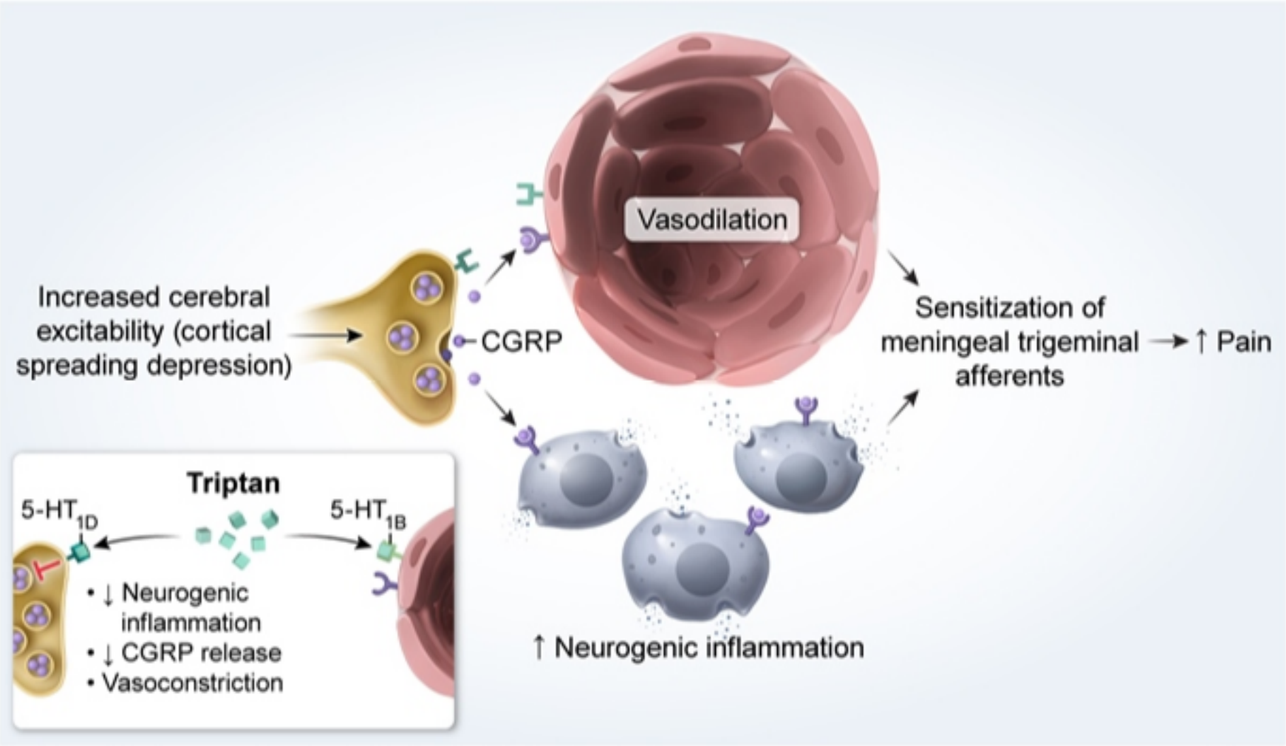

CGRP = calcitonin gene-related peptide; **5-HT** = 5-hydroxytryptamine.

©UWorld

Zoom In Zoom Out Reset Add To Flash Card

This patient with a normal neurologic examination has unilateral headache associated with **nausea and vomiting**, photophobia, and a visual aura.

Exhibit Display

Physiologic causes of nausea

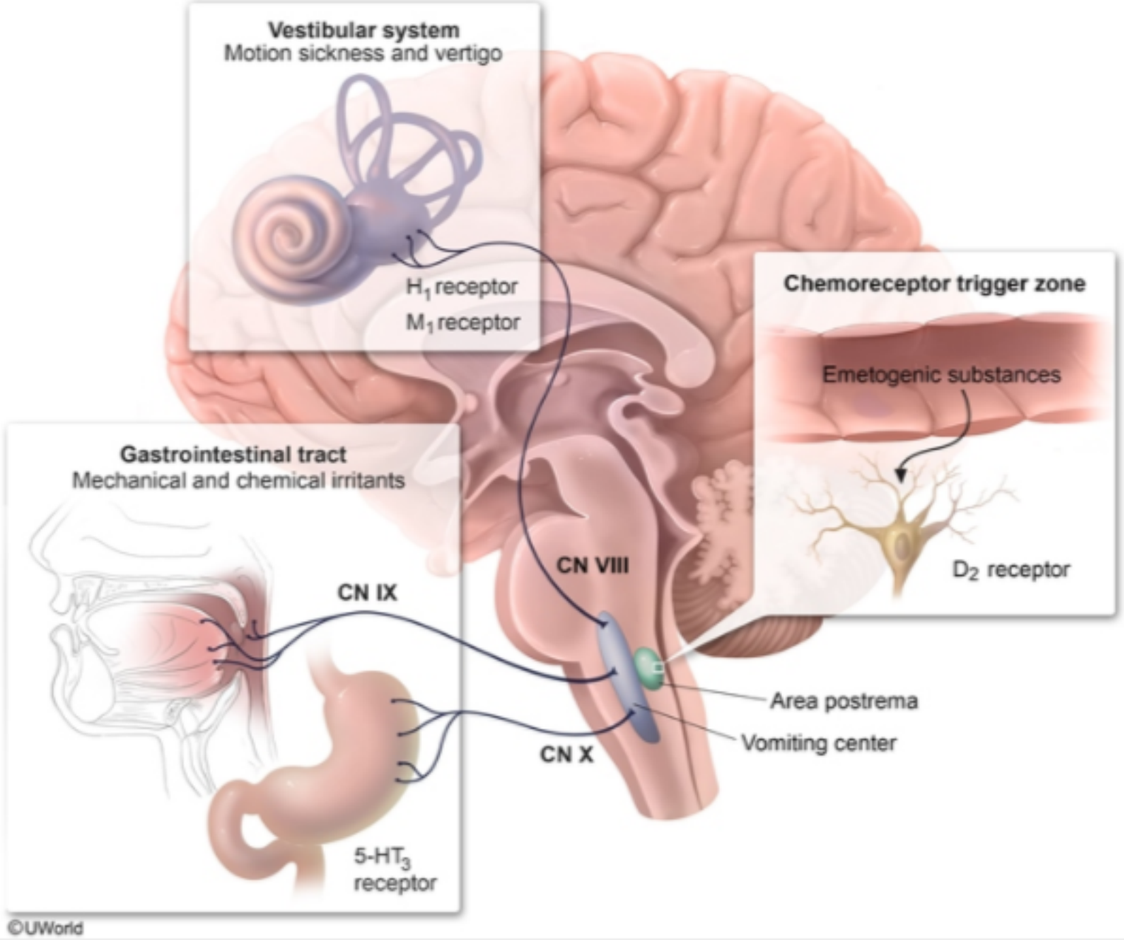

Zoom In Zoom Out Reset Add To Flash Card

A 36-year-old male is undergoing a major surgical procedure under general anesthesia. A fluorinated inhaled anesthetic (isoflurane) is used to achieve the desirable depth of central nervous system depression. An increase in which of the following parameters is most likely to happen during the anesthesia in this patient?

A. Glomerular filtration rate (GFR)

B. Effective renal plasma flow

C. Left ventricular ejection fraction (EF)

D. Hepatic blood flow

E. Cerebral blood flow

Submit

A 36-year-old male is undergoing a major surgical procedure under general anesthesia. A fluorinated inhaled anesthetic (isoflurane) is used to achieve the desirable depth of central nervous system depression. An increase in which of the following parameters is most likely to happen during the anesthesia in this patient?

A. Glomerular filtration rate (GFR)

B. Effective renal plasma flow

C. Left ventricular ejection fraction (EF)

D. Hepatic blood flow

E. Cerebral blood flow

Submit

A 36-year-old male is undergoing a major surgical procedure under general anesthesia. A fluorinated inhaled anesthetic (isoflurane) is used to achieve the desirable depth of central nervous system depression. An increase in which of the following parameters is most likely to happen during the anesthesia in this patient?

A. Glomerular filtration rate (GFR) (7%)

B. Effective renal plasma flow (7%)

C. Left ventricular ejection fraction (EF) (7%)

D. Hepatic blood flow (14%)

✓ E. Cerebral blood flow (62%)

Omitted
Correct answer
E

62%
Answered correctly

33 secs
Time Spent

02/03/2020
Last Updated

Explanation

General anesthesia encompasses loss of consciousness, analgesia, amnesia, skeletal muscle relaxation and inhibition of reflexes. This complex of symptoms occurs due to the inhibition of electrical activity of neurons. Most of inhalation anesthetics, barbiturates, and benzodiazepines achieve CNS depression by influencing GABA receptors and increasing the inhibitory action of GABA. Inhaled anesthetics have also been shown to affect potassium channels in the neuronal membranes and lock them in the state of hyperpolarization. They may also affect nicotinic and glycine receptors.

Apart from their desirable action on CNS, inhalation anesthetics affect almost all organ systems of the body.

General anesthesia encompasses loss of consciousness, analgesia, amnesia, skeletal muscle relaxation and inhibition of reflexes. This complex of symptoms occurs due to the inhibition of electrical activity of neurons. Most of inhalation anesthetics, barbiturates, and benzodiazepines achieve CNS depression by influencing GABA receptors and increasing the inhibitory action of GABA. Inhaled anesthetics have also been shown to affect potassium channels in the neuronal membranes and lock them in the state of hyperpolarization. They may also affect nicotinic and glycine receptors.

Apart from their desirable action on CNS, inhalation anesthetics affect almost all organ systems of the body.

1. Cardiovascular effects include myocardial depression that leads to a decrease in cardiac output and an increase in atrial and ventricular pressures. Hypotension associated with fluorinated anesthetics is a result of decrease in cardiac output.
2. Respiratory: all inhalation anesthetics, except nitrous oxide, are respiratory depressants. They decrease tidal volume and minute ventilation and cause hypercapnia. Another undesirable effect is the suppression of mucociliary clearance, which may predispose to postoperative atelectasis. Halothane and sevoflurane have bronchodilation properties and are preferred in patients with asthma.
3. In the brain, fluorinated anesthetics decrease vascular resistance and lead to an increase in cerebral blood flow. It is an undesirable effect as it results in increased intracranial pressure.
4. In kidneys, inhaled anesthetics decrease glomerular filtration rate, increase renal vascular resistance and decrease renal plasma flow.
5. Fluorinated anesthetics decrease hepatic blood flow.

(Choices A and B) Renal function in general anesthesia is characterized by decrease in glomerular filtration rate and decrease in renal plasma flow.

(Choice C) Fluorinated anesthetics are myocardial depressants. They decrease cardiac output which leads to hypotension.

(Choice D) Fluorinated anesthetics decrease hepatic blood flow.

Educational Objective:
Almost all volatile anesthetics increase cerebral blood flow. It is an undesirable effect as it results in increased ICP. Other important effects of inhalation anesthetics are myocardial depression, hypotension, respiratory depression and decreased renal function.

Pharmacology	Nervous System	Anesthesia
Subject	System	Topic

A 58-year-old man comes to the office due to lower extremity pain. The patient began experiencing tingly discomfort in his toes a year ago, especially at night when the sheets touched his skin. Since then, the symptoms have progressed to a burning and stabbing pain in his feet and lower legs. He was diagnosed with diabetes mellitus 8 years ago and hypertension 3 years ago. The patient quit smoking 20 years ago and does not use alcohol. Blood pressure is 126/70 mm Hg and pulse is 68/min. Lower extremity examination shows normal-appearing skin. Touching the feet elicits a sensation of burning pain. There is loss of vibration sensation in the toes, and the ankle reflex is absent bilaterally. Which of the following is the best initial pharmacotherapy for this patient's symptoms?

A. Amitriptyline
B. Clonazepam
C. Fluoxetine
D. Naproxen
E. Oxycodone
F. Pyridoxine

Submit

A 58-year-old man comes to the office due to lower extremity pain. The patient began experiencing tingly discomfort in his toes a year ago, especially at night when the sheets touched his skin. Since then, the symptoms have progressed to a burning and stabbing pain in his feet and lower legs. He was diagnosed with diabetes mellitus 8 years ago and hypertension 3 years ago. The patient quit smoking 20 years ago and does not use alcohol. Blood pressure is 126/70 mm Hg and pulse is 68/min. Lower extremity examination shows normal-appearing skin. Touching the feet elicits a sensation of burning pain. There is loss of vibration sensation in the toes, and the ankle reflex is absent bilaterally. Which of the following is the best initial pharmacotherapy for this patient's symptoms?

- ✓ A. Amitriptyline (62%)
- B. Clonazepam (3%)
- C. Fluoxetine (9%)
- D. Naproxen (6%)
- E. Oxycodone (2%)
- F. Pyridoxine (14%)

Omitted
Correct answer
A

62%
Answered correctly

01 sec
Time Spent

01/31/2020
Last Updated

Explanation

Distal symmetric polyneuropathy	
	• Diabetes mellitus (diabetic neuropathy)

A 58-year-old man comes to the office due to lower extremity pain. The patient began experiencing tingly discomfort in his toes a year ago, especially at night when the sheets touched his skin. Since then, the symptoms have progressed to a burning and stabbing pain in his feet and lower legs. He was diagnosed with diabetes mellitus 8 years ago and hypertension 3 years ago. The patient quit smoking 20 years ago and does not use alcohol. Blood pressure is 126/70 mm Hg and pulse is 68/min. Lower extremity examination shows normal-appearing skin. Touching the feet elicits a sensation of burning pain. There is loss of vibration sensation in the toes, and the ankle reflex is absent bilaterally. Which of the following is the best initial pharmacotherapy for this patient's symptoms?

- ✓ A. Amitriptyline (62%)
- B. Clonazepam (3%)
- C. Fluoxetine (9%)
- D. Naproxen (6%)
- E. Oxycodone (2%)
- F. Pyridoxine (14%)

Omitted
Correct answer
A

62%
Answered correctly

01 sec
Time Spent

01/31/2020
Last Updated

Explanation

Distal symmetric polyneuropathy	
	• Diabetes mellitus (diabetic neuropathy)

Distal symmetric polyneuropathy	
Triggers	• Diabetes mellitus (diabetic neuropathy) • Long-standing HIV infection • Uremia • Toxicity (eg, alcohol abuse, chemotherapy, heavy metal exposure)
Pathophysiology	• Damage to distal sensory peripheral nerve axons
Manifestations	• Symptoms begin in toes/feet; progresses proximally over time • Distal numbness, tingling, pins & needles sensation • ↓ Pain, temperature, touch & vibration sensation • ↓ Ankle/Babinski reflexes
Treatment	• Treat underlying cause • Pain management: gabapentinoid, tricyclic antidepressant, duloxetine &/or capsaicin cream

This patient with long-standing diabetes mellitus has tingling/burning pain in the feet, loss of vibration sensation, and loss of ankle reflexes, indicating **distal symmetric polyneuropathy** (diabetic neuropathy). Long-standing diabetes mellitus is often associated with damage to the **distal axons of sensory neurons** due to the accumulation of cross-linked glycosylated serum proteins in the vaso nervorum, which causes inflammation, vasoconstriction, and neuronal oxidative stress. Initial symptoms include tingling, numbness, and **burning pain** in the toes and/or feet. Sensation to pain, light touch, temperature, vibration, and proprioception are generally diminished in the affected area. Babinski and ankle reflex are often absent.

Treatment includes **glycemic control** and **foot care** to limit the development of ulcers and need for amputation. Patients with **painful** neuropathy also typically receive a serotonin-norepinephrine reuptake inhibitor (eg, duloxetine, venlafaxine), a gabapentinoid (eg, pregabalin, gabapentin), or a tricyclic antidepressant such as **amitriptyline**. Amitriptyline modulates pain transmission by inhibiting voltage-gated sodium channels in sensory nerves, blocking NMDA (excitatory) receptors in the spinal cord, and altering norepinephrine signaling in the brain.

duloxetine &/or capsaicin cream

This patient with long-standing diabetes mellitus has tingling/burning pain in the feet, loss of vibration sensation, and loss of ankle reflexes, indicating **distal symmetric polyneuropathy** (diabetic neuropathy). Long-standing diabetes mellitus is often associated with damage to the **distal axons of sensory neurons** due to the accumulation of cross-linked glycosylated serum proteins in the vaso nervorum, which causes inflammation, vasoconstriction, and neuronal oxidative stress. Initial symptoms include tingling, numbness, and **burning pain** in the toes and/or feet. Sensation to pain, light touch, temperature, vibration, and proprioception are generally diminished in the affected area. Babinski and ankle reflex are often absent.

Treatment includes **glycemic control** and **foot care** to limit the development of ulcers and need for amputation. Patients with **painful** neuropathy also typically receive a serotonin-norepinephrine reuptake inhibitor (eg, duloxetine, venlafaxine), a gabapentinoid (eg, pregabalin, gabapentin), or a tricyclic antidepressant such as **amitriptyline**. Amitriptyline modulates pain transmission by inhibiting voltage-gated sodium channels in sensory nerves, blocking NMDA (excitatory) receptors in the spinal cord, and altering norepinephrine signaling in the brain.

(Choice B) Benzodiazepines (eg, clonazepam) are often used for anxiety, muscle relaxation, or nausea. They are not typically used for neuropathic pain.

(Choice C) Although selective serotonin reuptake inhibitors (eg, fluoxetine) are often used for depression and anxiety, they are not often employed for neuropathic pain. In contrast, serotonin-norepinephrine reuptake inhibitors (eg, duloxetine, venlafaxine) are often used as first-line treatment to manage painful diabetic neuropathy; these agents alter central transmission of pain by increasing norepinephrine in the central synapses.

(Choice D) Nonsteroidal anti-inflammatory drugs such as naproxen are prescribed for acute painful conditions such as back pain, muscle strain, or bone fracture. However, they have limited efficacy for neuropathic pain.

(Choice E) Opioid pain medications (eg, oxycodone) are not recommended for most patients with neuropathic pain due to their questionable efficacy and risk of dependence/abuse/addiction. Patients with neuropathic pain should first be given a trial of an antidepressant or gabapentinoid.

(Choice F) Certain patients taking isoniazid require pyridoxine supplementation to prevent the development of drug-induced peripheral neuropathy. This patient is not taking isoniazid; therefore, pyridoxine supplementation would not be helpful.

Educational objective:

Patients with long-standing, poorly controlled diabetes mellitus are at high risk for developing distal symmetric polyneuropathy (diabetic

Treatment includes **glycemic control** and **foot care** to limit the development of ulcers and need for amputation. Patients with **painful** neuropathy also typically receive a serotonin-norepinephrine reuptake inhibitor (eg, duloxetine, venlafaxine), a gabapentinoid (eg, pregabalin, gabapentin), or a tricyclic antidepressant such as **amitriptyline**. Amitriptyline modulates pain transmission by inhibiting voltage-gated sodium channels in sensory nerves, blocking NMDA (excitatory) receptors in the spinal cord, and altering norepinephrine signaling in the brain.

(Choice B) Benzodiazepines (eg, clonazepam) are often used for anxiety, muscle relaxation, or nausea. They are not typically used for neuropathic pain.

(Choice C) Although selective serotonin reuptake inhibitors (eg, fluoxetine) are often used for depression and anxiety, they are not often employed for neuropathic pain. In contrast, serotonin-norepinephrine reuptake inhibitors (eg, duloxetine, venlafaxine) are often used as first-line treatment to manage painful diabetic neuropathy; these agents alter central transmission of pain by increasing norepinephrine in the central synapses.

(Choice D) Nonsteroidal anti-inflammatory drugs such as naproxen are prescribed for acute painful conditions such as back pain, muscle strain, or bone fracture. However, they have limited efficacy for neuropathic pain.

(Choice E) Opioid pain medications (eg, oxycodone) are not recommended for most patients with neuropathic pain due to their questionable efficacy and risk of dependence/abuse/addiction. Patients with neuropathic pain should first be given a trial of an antidepressant or gabapentinoid.

(Choice F) Certain patients taking isoniazid require pyridoxine supplementation to prevent the development of drug-induced peripheral neuropathy. This patient is not taking isoniazid; therefore, pyridoxine supplementation would not be helpful.

Educational objective:
Patients with long-standing, poorly controlled diabetes mellitus are at high risk for developing distal symmetric polyneuropathy (diabetic neuropathy). Symptoms generally include progressive numbness, tingling, and burning/stabbing pain in the feet and/or toes that progresses proximally. Painful neuropathy is treated with serotonin-norepinephrine reuptake inhibitors, gabapentinoids, or tricyclic antidepressants.

Pharmacology	Nervous System	Peripheral neuropathy
Subject	System	Topic

Copyright © UWorld. All rights reserved.

A 66-year-old man comes to the office with diplopia that progressively worsens toward the end of the day. The patient has no shortness of breath, trouble swallowing, or generalized weakness. He is currently receiving low-dose pyridostigmine for treatment of his condition and claims good compliance without significant side effects. Physical examination reveals fatigable asymmetric ptosis and binocular horizontal diplopia. Infusion of edrophonium elicits a significant improvement in his symptoms. Which of the following is the best next step in management of this patient?

A. Add atropine

B. Administer pralidoxime

C. Change long-term therapy to edrophonium

D. Increase pyridostigmine dosage

E. Stop pyridostigmine temporarily

Submit

A 66-year-old man comes to the office with diplopia that progressively worsens toward the end of the day. The patient has no shortness of breath, trouble swallowing, or generalized weakness. He is currently receiving low-dose pyridostigmine for treatment of his condition and claims good compliance without significant side effects. Physical examination reveals fatigable asymmetric ptosis and binocular horizontal diplopia. Infusion of edrophonium elicits a significant improvement in his symptoms. Which of the following is the best next step in management of this patient?

- A. Add atropine (2%)
- B. Administer pralidoxime (4%)
- C. Change long-term therapy to edrophonium (4%)
- ✓ D. Increase pyridostigmine dosage (78%)
- E. Stop pyridostigmine temporarily (10%)

Omitted
Correct answer
D

78%
Answered correctly

02 secs
Time Spent

03/25/2020
Last Updated

Explanation

Myasthenia gravis is an autoimmune disease caused by autoantibodies directed against nicotinic acetylcholine receptors on the postsynaptic membrane of the neuromuscular junction. Action potential propagation is impaired in these patients as antibody binding leads to receptor degradation and complement-mediated damage of the postsynaptic membrane. Patients typically present with fluctuating weakness that worsens over the course of the day and most often involves the extraocular (eg, ptosis, diplopia) and bulbar (eg, fatigable chewing, dysphagia) muscles.

Acetylcholinesterase (AChE) is an enzyme that degrades acetylcholine in the synaptic cleft. Long-acting **AChE inhibitors** (eg, **pyridostigmine**) are used in the symptomatic treatment of myasthenia gravis as they increase acetylcholine concentration in the neuromuscular junction,

Explanation

Myasthenia gravis is an autoimmune disease caused by autoantibodies directed against nicotinic acetylcholine receptors on the postsynaptic membrane of the neuromuscular junction. Action potential propagation is impaired in these patients as antibody binding leads to receptor degradation and complement-mediated damage of the postsynaptic membrane. Patients typically present with fluctuating weakness that worsens over the course of the day and most often involves the extraocular (eg, ptosis, diplopia) and bulbar (eg, fatigable chewing, dysphagia) muscles.

Acetylcholinesterase (AChE) is an enzyme that degrades acetylcholine in the synaptic cleft. Long-acting **AChE inhibitors** (eg, **pyridostigmine**) are used in the symptomatic treatment of myasthenia gravis as they increase acetylcholine concentration in the neuromuscular junction, prolonging its effect on the postsynaptic membrane.

Exacerbations of myasthenia gravis in patients being treated with AChE inhibitors may occur for 2 reasons. First, if the patient is undertreated (receives suboptimal doses of medication), not enough acetylcholine is available in the neuromuscular junction (**myasthenic crisis**). Infusion of the short-acting AChE inhibitor edrophonium (**Tensilon test**) increases neuromuscular transmission and can provide temporary improvement in symptoms **(Choice C)**. The pyridostigmine dose should be increased in the long-term management of these patients.

The second (rare) cause of exacerbation is **cholinergic crisis**. In this condition, a patient receives inappropriately high doses of AChE inhibitor and has excessive acetylcholine in the synaptic cleft. This causes excessive stimulation of the skeletal muscles and results in muscle that is refractory to future impulses. Cholinergic crisis also presents with muscle weakness; however, because the neuromuscular junction becomes insensitive to acetylcholine, edrophonium infusion produces no improvement in symptoms. AChE inhibitors should be temporarily discontinued in patients with cholinergic crisis **(Choice E)**.

(Choice A) Atropine is a muscarinic acetylcholine receptor antagonist that may be used in organophosphate poisoning and as a mydriatic agent (dilates pupils). However, it does not affect nicotinic receptors and is not used to treat myasthenic crisis.

(Choice B) Pralidoxime is also used in organophosphate poisoning. Pralidoxime reverses the effects of both muscarinic and nicotinic overstimulation by "regenerating" AChE in the neuromuscular junction.

Educational objective:
Exacerbation of myasthenia gravis in a patient treated with long-acting acetylcholinesterase inhibitors (eg, pyridostigmine) occurs due to myasthenic or cholinergic crisis. The edrophonium (Tensilon) test helps to differentiate these 2 conditions. Clinical improvement after

1
2
3
4
5
6
7
8
9
10
11
12
13
14
15
16
17
18
19
20
21
22

Explanation

Exhibit Display

Zoom In | Zoom Out | Reset | Add To New Card | Existing Card

myasthenic or cholinergic crisis. The edrophonium (Tensilon) test helps to differentiate these 2 conditions. Clinical improvement after

prolonging its effect on the postsynaptic membrane.

Exacerbations of myasthenia gravis in patients being treated with AChE inhibitors may occur for 2 reasons. First, if the patient is undertreated (receives suboptimal doses of medication), not enough acetylcholine is available in the neuromuscular junction (**myasthenic crisis**). Infusion of the short-acting AChE inhibitor edrophonium (**Tensilon test**) increases neuromuscular transmission and can provide temporary improvement in symptoms **(Choice C)**. The pyridostigmine dose should be increased in the long-term management of these patients.

The second (rare) cause of exacerbation is **cholinergic crisis**. In this condition, a patient receives inappropriately high doses of AChE inhibitor and has excessive acetylcholine in the synaptic cleft. This causes excessive stimulation of the skeletal muscles and results in muscle that is refractory to future impulses. Cholinergic crisis also presents with muscle weakness; however, because the neuromuscular junction becomes insensitive to acetylcholine, edrophonium infusion produces no improvement in symptoms. AChE inhibitors should be temporarily discontinued in patients with cholinergic crisis **(Choice E)**.

(Choice A) Atropine is a muscarinic acetylcholine receptor antagonist that may be used in organophosphate poisoning and as a mydriatic agent (dilates pupils). However, it does not affect nicotinic receptors and is not used to treat myasthenic crisis.

(Choice B) Pralidoxime is also used in organophosphate poisoning. Pralidoxime reverses the effects of both muscarinic and nicotinic overstimulation by "regenerating" AChE in the neuromuscular junction.

Educational objective:
Exacerbation of myasthenia gravis in a patient treated with long-acting acetylcholinesterase inhibitors (eg, pyridostigmine) occurs due to myasthenic or cholinergic crisis. The edrophonium (Tensilon) test helps to differentiate these 2 conditions. Clinical improvement after edrophonium administration indicates that the patient is undertreated (myasthenic crisis).

References

- Myasthenia gravis: a review.

Pharmacology	Nervous System	Myasthenia gravis
Subject	System	Topic

Copyright © UWorld. All rights reserved.

A 75-year-old female is brought to your office by her son because of worsening forgetfulness over the past few years and several recent episodes of getting lost while performing errands around the house. She exhibits no signs or symptoms of depression. On physical examination, the patient has a blood pressure of 139/88 mmHg. She is alert and cooperative but disoriented to time and can only recall 1 of 3 items on a short term memory test. An extensive work-up, including appropriate laboratory tests and a brain MRI scan, reveals diffuse cortical atrophy with no other abnormalities. This patient would likely benefit from treatment with which of the following:

A. Lorazepam
B. Desipramine
C. Haloperidol
D. Donepezil
E. Folic acid
F. Vitamin A
G. Sertraline
H. Melatonin

Submit

A 75-year-old female is brought to your office by her son because of worsening forgetfulness over the past few years and several recent episodes of getting lost while performing errands around the house. She exhibits no signs or symptoms of depression. On physical examination, the patient has a blood pressure of 139/88 mmHg. She is alert and cooperative but disoriented to time and can only recall 1 of 3 items on a short term memory test. An extensive work-up, including appropriate laboratory tests and a brain MRI scan, reveals diffuse cortical atrophy with no other abnormalities. This patient would likely benefit from treatment with which of the following:

- A. Lorazepam (1%)
- B. Desipramine (7%)
- C. Haloperidol (2%)
- ✓ D. Donepezil (73%)
- E. Folic acid (2%)
- F. Vitamin A (2%)
- G. Sertraline (7%)
- H. Melatonin (1%)

Omitted
Correct answer
D

73%
Answered correctly

02 secs
Time Spent

02/03/2020
Last Updated

Explanation

Correct answer
D

Answered correctly

Time Spent

Last Updated

Explanation

This is a patient with chronically progressive dementia. The MRI findings of cortical atrophy and the absence of other reversible causes of dementia point to a clinical diagnosis of Alzheimer's disease (AD), a diagnosis of exclusion. Currently available AD-specific therapies offer either: 1.) Enhanced cholinergic neurotransmission, 2.) Neuroprotection via antioxidants, or 3.) NMDA receptor antagonism. Of the answer choices provided, only donepezil, a cholinesterase inhibitor, is an AD medication. The cholinesterase inhibitors appear to improve cognition, behavior, and functioning in activities of daily living in AD patients. Although they do not appear to prevent the ultimate progression of cerebral neurodegeneration, the cholinesterase inhibitors may delay institutionalization and mortality.

Regarding the other classes of AD drugs, vitamin E (α-tocopherol) is a neuroprotective agent that may slow functional losses in AD. Memantine is a NMDA receptor antagonist. It is thought that CNS NMDA-receptor overstimulation by glutamate may contribute to AD symptoms.

(Choice A) In general, benzodiazepines should be avoided in AD given their depressive effects on cognition (e.g. lethargy, confusion). In some circumstances, however, they may be prescribed to AD patients to treat associated anxiety and insomnia.

The other agents listed do not have applications in AD.

Educational Objective:
A chronically progressive pre-senile dementia with cortical atrophy but no other radiological or laboratory abnormalities permits a clinical diagnosis of Alzheimer's disease (AD), which is a diagnosis of exclusion. Current AD-specific therapies include cholinesterase inhibitors (Donepezil), antioxidants (vitamin E), and NMDA receptor antagonists (e.g. memantine).

Pharmacology	Nervous System	Alzheimer disease
Subject	System	Topic

Copyright © UWorld. All rights reserved.

A 52-year-old woman comes to the office due to a hand tremor that has been present for several months. It is most prominent while she is carrying out simple daily activities such as drinking from a glass or pouring from a tea kettle. When asked if anything improves the tremor, the patient mentions that it subsides somewhat when she drinks small amounts of alcohol. Family history is significant for similar problems in her mother. Vital signs are normal. Neurologic examination shows bilateral tremor in the upper extremities. Which of the following is the best treatment for this patient?

A. Benztropine
B. Clozapine
C. Diazepam
D. Haloperidol
E. L-DOPA
F. Propranolol

Submit

A 52-year-old woman comes to the office due to a hand tremor that has been present for several months. It is most prominent while she is carrying out simple daily activities such as drinking from a glass or pouring from a tea kettle. When asked if anything improves the tremor, the patient mentions that it subsides somewhat when she drinks small amounts of alcohol. Family history is significant for similar problems in her mother. Vital signs are normal. Neurologic examination shows bilateral tremor in the upper extremities. Which of the following is the best treatment for this patient?

- A. Benztropine (12%)
- B. Clozapine (2%)
- C. Diazepam (19%)
- D. Haloperidol (1%)
- E. L-DOPA (12%)
- ✓ F. Propranolol (52%)

Omitted
Correct answer
F

52%
Answered correctly

01 sec
Time Spent

04/01/2020
Last Updated

Explanation

This patient has **essential tremor**, the most commonly diagnosed movement disorder. Essential tremor is also referred to as **familial** tremor as it often follows **autosomal dominant** inheritance. A positive family history of tremor can sometimes assist in making the diagnosis. Essential tremor classically worsens while maintaining a particular posture (eg, when holding an object). Patients commonly report that their symptoms **improve with alcohol consumption**. **Propranolol** is the first-line treatment for essential tremor. This nonselective β-adrenergic antagonist is

Explanation

This patient has **essential tremor**, the most commonly diagnosed movement disorder. Essential tremor is also referred to as **familial** tremor as it often follows **autosomal dominant** inheritance. A positive family history of tremor can sometimes assist in making the diagnosis. Essential tremor classically worsens while maintaining a particular posture (eg, when holding an object). Patients commonly report that their symptoms **improve with alcohol consumption**. **Propranolol** is the first-line treatment for essential tremor. This nonselective β-adrenergic antagonist is thought to lessen the tremor via central nervous system effects.

(Choice A) Benztropine is an anticholinergic agent that can be used to treat tremor in Parkinson disease and to counteract the extrapyramidal side effects of neuroleptic medications such as haloperidol.

(Choices B and D) Haloperidol is most commonly used to treat the positive symptoms of psychosis (eg, delusions, hallucinations). Clozapine is an atypical antipsychotic that blocks D_2 (dopamine) and $5HT_2$ (serotonin) receptors in the CNS.

(Choice C) Diazepam is a benzodiazepine that is effective for treatment of seizures and alcohol withdrawal. This patient has had intention tremor for several months and family history is positive for essential tremor; these findings would make alcohol withdrawal very unlikely.

(Choice E) L-DOPA, or levodopa, is used in combination with the DOPA decarboxylase inhibitor carbidopa to treat Parkinson disease. Patients with Parkinson disease have a resting tremor.

Educational objective:
Essential tremor is the most common movement disorder. Patients experience a slowly progressive, symmetric postural and/or kinetic tremor that most commonly affects the upper extremities. Essential tremor is often inherited in an autosomal dominant fashion (referred to as familial tremor). First-line treatment is the nonspecific β-adrenergic antagonist propranolol.

Pharmacology	Nervous System	Tremor
Subject	System	Topic

Copyright © UWorld. All rights reserved.

1
2
3
4
5
6
7
8
9
10
11
12
13
14
15
16
17
18
19
20
21
22

A 56-year-old man is hospitalized due to worsening fever, chills, and perirectal pain. Physical examination reveals a large perirectal abscess. Empiric antibiotics are begun, and surgical drainage is planned. The patient receives succinylcholine and propofol prior to the procedure. The intraoperative course is uneventful, but postoperative spontaneous recovery of respiration and voluntary muscle activity does not occur. Mechanical respiratory support is continued, and several hours later, the patient is successfully weaned from the ventilator. Which of the following is the most likely underlying cause of this patient's postoperative complications?

A. Decreased renal clearance

B. Drug redistribution to other tissues

C. Genetic polymorphism

D. Impaired hepatic function

E. Neuromuscular junction autoantibodies

Submit

A 56-year-old man is hospitalized due to worsening fever, chills, and perirectal pain. Physical examination reveals a large perirectal abscess. Empiric antibiotics are begun, and surgical drainage is planned. The patient receives succinylcholine and propofol prior to the procedure. The intraoperative course is uneventful, but postoperative spontaneous recovery of respiration and voluntary muscle activity does not occur. Mechanical respiratory support is continued, and several hours later, the patient is successfully weaned from the ventilator. Which of the following is the most likely underlying cause of this patient's postoperative complications?

- A. Decreased renal clearance (8%)
- B. Drug redistribution to other tissues (15%)
- ✓ C. Genetic polymorphism (54%)
- D. Impaired hepatic function (10%)
- E. Neuromuscular junction autoantibodies (11%)

Omitted
Correct answer
C

54%
Answered correctly

01 sec
Time Spent

02/25/2020
Last Updated

Explanation

Succinylcholine is a depolarizing neuromuscular blocking agent used to induce skeletal relaxation during intubation and surgery. It acts as a **competitive agonist** of nicotinic acetylcholine receptors of the motor endplate, where it induces persistent depolarization, leading to endplate desensitization and skeletal muscle paralysis. Succinylcholine is rapidly metabolized by **plasma pseudocholinesterase**; only around 10% of the administered dose reaches the neuromuscular junction, where it typically has a duration of action of <10 minutes.

This patient, who developed **prolonged muscle weakness** (eg, failure of spontaneous respiration and voluntary muscle activity) after receiving

Succinylcholine is a depolarizing neuromuscular blocking agent used to induce skeletal relaxation during intubation and surgery. It acts as a **competitive agonist** of nicotinic acetylcholine receptors of the motor endplate, where it induces persistent depolarization, leading to endplate desensitization and skeletal muscle paralysis. Succinylcholine is rapidly metabolized by **plasma pseudocholinesterase**; only around 10% of the administered dose reaches the neuromuscular junction, where it typically has a duration of action of <10 minutes.

This patient, who developed **prolonged muscle weakness** (eg, failure of spontaneous respiration and voluntary muscle activity) after receiving succinylcholine, most likely has **pseudocholinesterase deficiency**, an autosomal recessive disorder caused by a **genetic polymorphism** in the *BCHE* gene. Patients are unable to metabolize succinylcholine, leading to a large amount of the drug reaching the neuromuscular junction and prolonged paralysis. Heterozygotes may experience double the normal duration of paralysis, and homozygotes can have persistent paralysis for **several hours**. Patients with pseudocholinesterase deficiency also experience prolonged effects of mivacurium (a nondepolarizing neuromuscular blocker) and cocaine.

(Choices A and D) Succinylcholine is metabolized by plasma pseudocholinesterase, not the liver or kidneys. Because pseudocholinesterase is produced in the liver, patients with severe liver disease may have prolonged drug effects due to impaired synthetic function. However, paralysis would not be expected to last for hours.

(Choice B) Propofol is highly lipid soluble and has a very short duration of action (seconds) because of rapid redistribution from the brain, where it activates the GABA-A receptor, to other tissues. Propofol is a hypnotic agent; it does not cause muscle paralysis.

(Choice E) Patients with myasthenia gravis (ie, autoantibodies to the acetylcholine receptors of the neuromuscular junction) have fewer active acetylcholine receptors and are therefore highly resistant to succinylcholine. Paralysis can occur with high doses but is unpredictable. Use is usually avoided in this population.

Educational objective:
Succinylcholine is a depolarizing neuromuscular blocking agent used to induce skeletal muscle relaxation; it typically has a very short duration of action due to metabolism by plasma pseudocholinesterase. Pseudocholinesterase deficiency is an autosomal recessive disorder that results in the inability to metabolize succinylcholine, leading to prolonged neuromuscular paralysis after drug administration.

Pharmacology	Nervous System	Neuromuscular blocker
Subject	System	Topic

1
2
3
4
5
6
7
8
9
10
11
12
13
14
15
16
17
18
19
20
21
22

A 70-year-old man comes to the physician with muscle rigidity that impairs his daily activities. He was diagnosed with Parkinson disease 5 years ago and takes levodopa/carbidopa. His initial response to the medication allowed him to continue all of his usual activities. Recently, the patient has been experiencing episodes of sudden restricted mobility lasting several hours, and sometimes he "freezes" altogether. These episodes alternate with symptom-free periods in which he is mobile and feels well. The patient desires relief as he believes he can still "do so much" with his life. During discussion of this patient's fluctuating mobility, which of the following should the physician emphasize?

A. Drug holidays are helpful

B. Drug response is unpredictable

C. Fluctuations are caused by enhanced drug metabolism

D. Fluctuations are temporary and will resolve spontaneously

E. Stopping carbidopa is the best management

Submit

A 70-year-old man comes to the physician with muscle rigidity that impairs his daily activities. He was diagnosed with Parkinson disease 5 years ago and takes levodopa/carbidopa. His initial response to the medication allowed him to continue all of his usual activities. Recently, the patient has been experiencing episodes of sudden restricted mobility lasting several hours, and sometimes he "freezes" altogether. These episodes alternate with symptom-free periods in which he is mobile and feels well. The patient desires relief as he believes he can still "do so much" with his life. During discussion of this patient's fluctuating mobility, which of the following should the physician emphasize?

- A. Drug holidays are helpful (22%)
- ✓ B. Drug response is unpredictable (35%)
- C. Fluctuations are caused by enhanced drug metabolism (26%)
- D. Fluctuations are temporary and will resolve spontaneously (10%)
- E. Stopping carbidopa is the best management (5%)

Omitted
Correct answer
B

35%
Answered correctly

01 sec
Time Spent

04/25/2020
Last Updated

Explanation

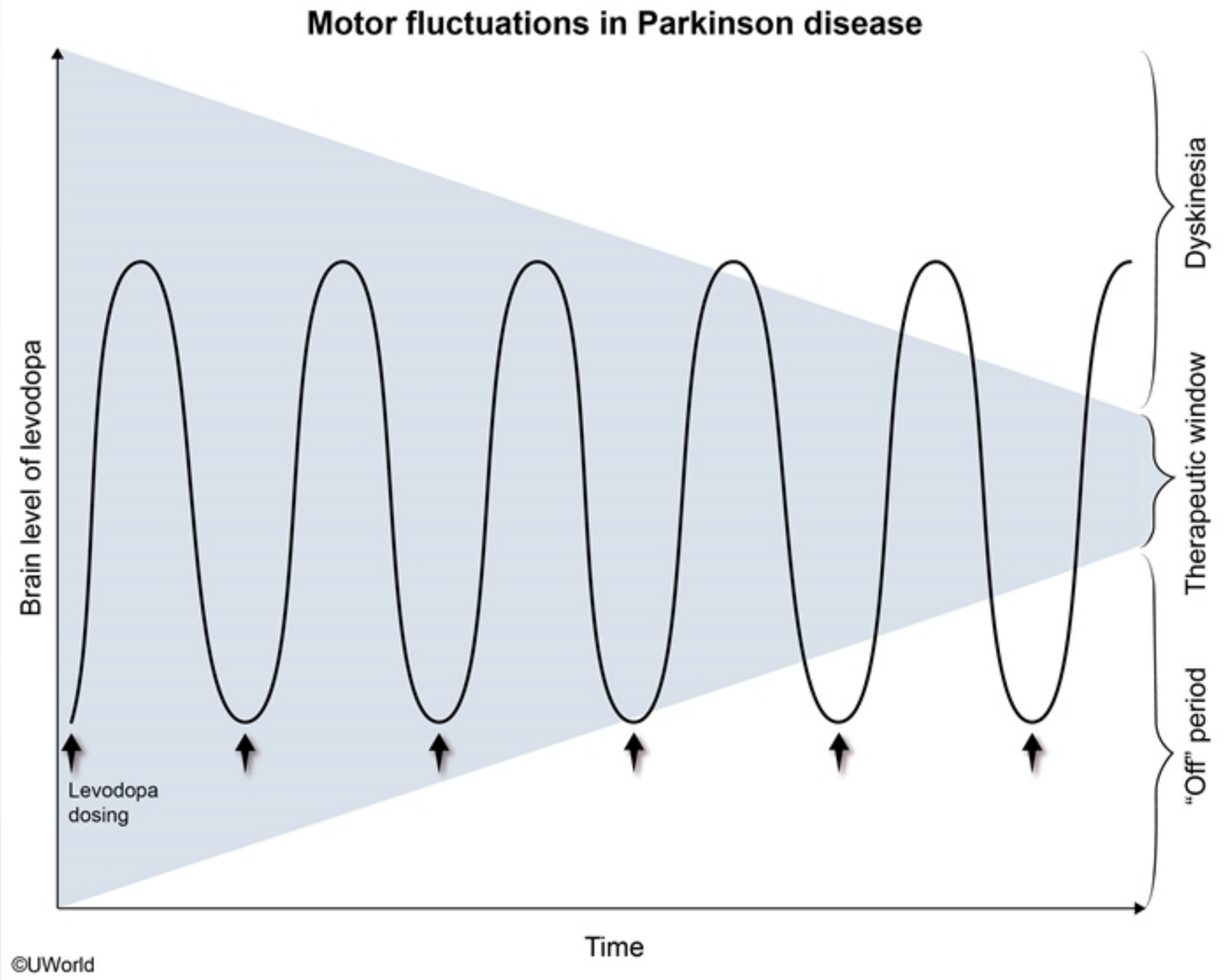

Long-term treatment of **Parkinson disease** (PD) with **levodopa** can be complicated by periodic fluctuations in motor function: patients have good mobility during "on" periods and increased bradykinesia/rigidity during "off" periods (**"on-off" phenomenon**). Oftentimes, these fluctuations appear to correlate with serum drug levels (eg, reduced mobility 4 hours after the last dose). As PD progresses, the therapeutic window for

©UWorld

Time

Long-term treatment of **Parkinson disease** (PD) with **levodopa** can be complicated by periodic fluctuations in motor function: patients have good mobility during "on" periods and increased bradykinesia/rigidity during "off" periods (**"on-off" phenomenon**). Oftentimes, these fluctuations appear to correlate with serum drug levels (eg, reduced mobility 4 hours after the last dose). As PD progresses, the therapeutic window for levodopa narrows, possibly due to natural or levodopa-induced **nigrostriatal degeneration**. As a result, small changes in serum drug levels can result in motor fluctuations (eg, mild elevations may result in dyskinesia, whereas slight reductions may result in bradykinesia/rigidity). In advanced PD, motor fluctuations can occur independently of medication dosing and may become unpredictable.

(Choice A) Drug holidays have not been shown to be effective in preventing motor fluctuations in PD. Also, stopping levodopa abruptly is not recommended as it could cause a condition similar to neuroleptic malignant syndrome.

(Choices C and D) Progressive nigrostriatal neurodegeneration, not enhanced drug metabolism, is thought to be responsible for motor fluctuations in PD. As such, motor fluctuations are not typically temporary or self-limiting and usually require long-term medical management.

(Choice E) Discontinuation of carbidopa (a decarboxylase inhibitor) is inappropriate as carbidopa reduces the peripheral conversion of levodopa to dopamine and consequently minimizes systemic side effects (eg, nausea/vomiting).

Educational objective:
Long-term treatment of Parkinson disease with levodopa can be complicated by periodic and sometimes unpredictable fluctuations in motor function. This "on-off" phenomenon is thought to be a consequence of progressive nigrostriatal neurodegeneration leading to a decreased therapeutic window for levodopa.

References

- Treatment of motor symptoms in advanced Parkinson's disease: a practical approach.

Pharmacology	Nervous System	Parkinson disease
Subject	System	Topic

Copyright © UWorld. All rights reserved.

A 26-year-old man comes to the office due to severe headaches that are increasing in frequency. The patient describes episodic, right-sided hemicranial throbbing or pulsating headaches accompanied by nausea and photophobia. The headaches began when he was in high school, but lately they have become more frequent and are affecting his work. The patient takes nonsteroidal analgesics and sumatriptan for the pain and metoclopramide for nausea. He has no other medical conditions and no drug allergies. Vital signs are within normal limits, and physical examination shows no abnormalities. A recent brain imaging study was normal. Which of the following pharmacotherapies would be most helpful to prevent recurrences of this patient's headache?

A. Capsaicin
B. Ergotamine
C. Hydrochlorothiazide
D. Sertraline
E. Topiramate

Submit

A 26-year-old man comes to the office due to severe headaches that are increasing in frequency. The patient describes episodic, right-sided hemicranial throbbing or pulsating headaches accompanied by nausea and photophobia. The headaches began when he was in high school, but lately they have become more frequent and are affecting his work. The patient takes nonsteroidal analgesics and sumatriptan for the pain and metoclopramide for nausea. He has no other medical conditions and no drug allergies. Vital signs are within normal limits, and physical examination shows no abnormalities. A recent brain imaging study was normal. Which of the following pharmacotherapies would be most helpful to prevent recurrences of this patient's headache?

- A. Capsaicin (3%)
- B. Ergotamine (25%)
- C. Hydrochlorothiazide (0%)
- D. Sertraline (8%)
- ✓ E. Topiramate (62%)

Omitted
Correct answer
E

62%
Answered correctly

01 sec
Time Spent

03/24/2020
Last Updated

Explanation

Migraine therapy	
Abortive	• Triptans • NSAIDs, acetaminophen

Migraine therapy	
Abortive	• Triptans • NSAIDs, acetaminophen • Antiemetics • Ergotamine
Preventive	• Anticonvulsants (topiramate or valproate) • Beta blockers • Antidepressants (tricyclic or venlafaxine)

NSAIDs = nonsteroidal anti-inflammatory drugs.

This patient has recurrent **migraine**, a disorder characterized by severe, unilateral headaches, frequently associated with nausea and sensitivity to light and sound. Migraine therapy is divided into abortive therapy for acute pain control and preventive therapy to reduce the frequency and severity of the headaches. Commonly used **abortive medications** include mild analgesics (eg, nonsteroidal anti-inflammatory drugs, acetaminophen), triptans (eg, sumatriptan), antiemetics (eg, metoclopramide, prochlorperazine), and ergotamines. These medications reduce symptoms at headache onset but do not prevent further headaches.

Patients with frequent migraines or significant impairment due to the symptoms warrant **preventive therapy**. **Topiramate** is an anticonvulsant that reduces the frequency of migraines. Other preventive medications include **beta blockers** (eg, metoprolol, propranolol), **tricyclic antidepressants** (eg, amitriptyline), and other anticonvulsants (eg, valproate).

(Choice A) Capsaicin is derived from chili peppers and is useful as a topical therapy for neuropathic or musculoskeletal pain; it is not useful for treatment of migraine.

(Choice B) Ergotamine has both agonist and antagonist activities on multiple neurotransmitters (eg, dopamine, serotonin, epinephrine) and acts as a vasoconstrictor. It is used for migraine abortion, not prevention.

(Choice C) Hydrochlorothiazide is an antihypertensive that reduces sodium reabsorption in the distal convoluted tubule. Although beta blockers (another type of antihypertensive) are useful for migraine prevention, hydrochlorothiazide is not indicated for treatment of migraines.

This patient has recurrent **migraine**, a disorder characterized by severe, unilateral headaches, frequently associated with nausea and sensitivity to light and sound. Migraine therapy is divided into abortive therapy for acute pain control and preventive therapy to reduce the frequency and severity of the headaches. Commonly used **abortive medications** include mild analgesics (eg, nonsteroidal anti-inflammatory drugs, acetaminophen), triptans (eg, sumatriptan), antiemetics (eg, metoclopramide, prochlorperazine), and ergotamines. These medications reduce symptoms at headache onset but do not prevent further headaches.

Patients with frequent migraines or significant impairment due to the symptoms warrant **preventive therapy**. **Topiramate** is an anticonvulsant that reduces the frequency of migraines. Other preventive medications include **beta blockers** (eg, metoprolol, propranolol), **tricyclic antidepressants** (eg, amitriptyline), and other anticonvulsants (eg, valproate).

(Choice A) Capsaicin is derived from chili peppers and is useful as a topical therapy for neuropathic or musculoskeletal pain; it is not useful for treatment of migraine.

(Choice B) Ergotamine has both agonist and antagonist activities on multiple neurotransmitters (eg, dopamine, serotonin, epinephrine) and acts as a vasoconstrictor. It is used for migraine abortion, not prevention.

(Choice C) Hydrochlorothiazide is an antihypertensive that reduces sodium reabsorption in the distal convoluted tubule. Although beta blockers (another type of antihypertensive) are useful for migraine prevention, hydrochlorothiazide is not indicated for treatment of migraines.

(Choice D) Sertraline is a selective serotonin reuptake inhibitor (SSRI) used for depression and anxiety. Although tricyclic antidepressants are used for migraine prevention, SSRIs have not been shown to prevent migraines.

Educational objective:
Migraine is an episodic disorder characterized by severe, often unilateral headache, commonly associated with nausea and sensitivity to light and sound. Treatment is divided into abortive therapy (eg, mild analgesics, triptans, antiemetics, ergotamines) for acute symptoms and preventive therapy (eg, beta blockers, tricyclic antidepressants, anticonvulsants [topiramate, valproate]) to reduce the frequency of headaches.

Pharmacology	Nervous System	Migraine
Subject	System	Topic

Copyright © UWorld. All rights reserved.

A 6-year-old boy is brought to the office by his mother due to difficulty with his behavior in school. She says that his teacher is concerned that he does not pay attention in class and his grades are dropping to the point he may need medication to help him focus. The patient's mother has noticed that at home he seems to stare into space for several seconds, multiple times throughout the day. This occurs even when he is watching his favorite television show, and he seems to ignore her when she calls his name. The patient has no previous medical problems and takes no medications. He has an older brother with attention-deficit hyperactivity disorder and an aunt with epilepsy. Which of the following is the most appropriate pharmacotherapy for this patient?

A. Carbamazepine
B. Ethosuximide
C. Lorazepam
D. Methylphenidate
E. Phenobarbital

Submit

A 6-year-old boy is brought to the office by his mother due to difficulty with his behavior in school. She says that his teacher is concerned that he does not pay attention in class and his grades are dropping to the point he may need medication to help him focus. The patient's mother has noticed that at home he seems to stare into space for several seconds, multiple times throughout the day. This occurs even when he is watching his favorite television show, and he seems to ignore her when she calls his name. The patient has no previous medical problems and takes no medications. He has an older brother with attention-deficit hyperactivity disorder and an aunt with epilepsy. Which of the following is the most appropriate pharmacotherapy for this patient?

- A. Carbamazepine (2%)
- ✓ B. Ethosuximide (83%)
- C. Lorazepam (0%)
- D. Methylphenidate (11%)
- E. Phenobarbital (1%)

Omitted
Correct answer
B

83%
Answered correctly

02 secs
Time Spent

03/26/2020
Last Updated

Explanation

Absence seizures	
	• Sudden impairment of consciousness ("staring spells") • Preserved muscle tone

Absence seizures	
Clinical features	• Sudden impairment of consciousness ("staring spells") • Preserved muscle tone • Unresponsive to tactile/verbal stimulation • Short duration (<20 sec) • Simple automatisms frequently present • Easily provoked by hyperventilation
Diagnosis	EEG: 3-Hz spike-wave discharges during episodes
Treatment	Ethosuximide

EEG = electroencephalogram.

Absence seizures, a type of **generalized** epilepsy, present in children age 4-10 as brief **staring spells** with a momentary lapse in consciousness. Automatisms, such as rhythmic blinking or repetitive lip smacking, may occur. Most absence seizures last approximately 10 seconds, and behavior and awareness typically return immediately to normal following an attack. The patient experiences **no postictal** period and usually has no recollection that a seizure has occurred. Absence seizures are characteristically provoked by **hyperventilation**, and electroencephalogram will show generalized **3-Hz spike-wave** complexes.

Treatment of absence seizures is typically with **ethosuximide**, which inhibits T-type calcium channels in thalamic neurons. Valproate can also be used if first-line therapy is not tolerated or ineffective. Childhood absence epilepsy is typically benign, and seizures often resolve before puberty.

(Choices A and E) Narrow-spectrum anticonvulsants (eg, carbamazepine, gabapentin, phenobarbital, phenytoin) are generally favored for focal-onset seizures. Carbamazepine can worsen absence seizures and phenobarbital is ineffective in these patients.

(Choice C) Lorazepam is a benzodiazepine that is used as a first-line anticonvulsant in a patient with status epilepticus.

(Choice D) Methylphenidate is an indirect-acting sympathomimetic used to treat attention-deficit hyperactivity disorder (ADHD). Although ADHD may present similarly with "inattention," staring episodes consistent with absence seizures do not occur out of boredom or lack of focus and cannot

EEG = electroencephalogram.

Absence seizures, a type of **generalized** epilepsy, present in children age 4-10 as brief **staring spells** with a momentary lapse in consciousness. Automatisms, such as rhythmic blinking or repetitive lip smacking, may occur. Most absence seizures last approximately 10 seconds, and behavior and awareness typically return immediately to normal following an attack. The patient experiences **no postictal** period and usually has no recollection that a seizure has occurred. Absence seizures are characteristically provoked by **hyperventilation**, and electroencephalogram will show generalized **3-Hz spike-wave** complexes.

Treatment of absence seizures is typically with **ethosuximide**, which inhibits T-type calcium channels in thalamic neurons. Valproate can also be used if first-line therapy is not tolerated or ineffective. Childhood absence epilepsy is typically benign, and seizures often resolve before puberty.

(Choices A and E) Narrow-spectrum anticonvulsants (eg, carbamazepine, gabapentin, phenobarbital, phenytoin) are generally favored for focal-onset seizures. Carbamazepine can worsen absence seizures and phenobarbital is ineffective in these patients.

(Choice C) Lorazepam is a benzodiazepine that is used as a first-line anticonvulsant in a patient with status epilepticus.

(Choice D) Methylphenidate is an indirect-acting sympathomimetic used to treat attention-deficit hyperactivity disorder (ADHD). Although ADHD may present similarly with "inattention," staring episodes consistent with absence seizures do not occur out of boredom or lack of focus and cannot be interrupted by verbal/tactile stimuli.

Educational objective:
Absence seizures are a type of generalized epilepsy characterized by brief staring spells with momentary loss of awareness followed by an abrupt return to full consciousness. A classic 3-Hz spike-wave is seen on electroencephalogram; the treatment is ethosuximide.

References

- Ethosuximide, sodium valproate or lamotrigine for absence seizures in children and adolescents.

Pharmacology	Nervous System	Seizures
Subject	System	Topic

Copyright © UWorld. All rights reserved.

A 50-year-old man is brought to the emergency department after developing blurred vision and confusion. Earlier today, he was clearing and burning foliage and weeds on his property. His medical history is insignificant, and he does not take any medications. The patient has no history of illicit drug use. Temperature is 38.9 C (102 F), blood pressure is 110/76 mm Hg, pulse is 120/min, and respirations are 16/min. He is disoriented to time, place, and person. Physical examination shows flushed skin and dry oral mucosa. Both pupils are dilated and nonreactive to light and accommodation. Bowel sounds are decreased. Which of the following drugs can potentially reverse this patient's condition?

- A. Atropine
- B. Benztropine
- C. Diazepam
- D. Haloperidol
- E. Metoprolol
- F. Morphine
- G. Naloxone
- H. Physostigmine
- I. Thiamine

Submit

A 50-year-old man is brought to the emergency department after developing blurred vision and confusion. Earlier today, he was clearing and burning foliage and weeds on his property. His medical history is insignificant, and he does not take any medications. The patient has no history of illicit drug use. Temperature is 38.9 C (102 F), blood pressure is 110/76 mm Hg, pulse is 120/min, and respirations are 16/min. He is disoriented to time, place, and person. Physical examination shows flushed skin and dry oral mucosa. Both pupils are dilated and nonreactive to light and accommodation. Bowel sounds are decreased. Which of the following drugs can potentially reverse this patient's condition?

- A. Atropine (19%)
- B. Benztropine (2%)
- C. Diazepam (0%)
- D. Haloperidol (0%)
- E. Metoprolol (1%)
- F. Morphine (0%)
- G. Naloxone (2%)
- ✓ H. Physostigmine (72%)
- I. Thiamine (0%)

Omitted
Correct answer
H

72%
Answered correctly

01 sec
Time Spent

02/14/2020
Last Updated

Explanation

Anticholinergic toxicity	
Symptom	**Mechanism**
"Hot as a hare" ↑ Body temperature	↓ Sweating leads to ↓ heat dissipation
"Dry as a bone" ↓ Secretions (eg, mucous membranes, sweat glands)	↓ Glandular secretion & smooth muscle contraction
"Red as a beet" Flushed skin	Superficial vasodilation from ↑ body heat
"Blind as a bat" Cycloplegia, mydriasis	Paralysis of ciliary muscle & iris sphincter
"Mad as a hatter" Altered mental status	Permeates blood-brain barrier & affects CNS pathways
"Full as a flask" Urinary retention Constipation	↓ Detrusor contraction & ↓ internal urethral sphincter relaxation ↓ Intestinal smooth muscle contraction
"Fast as a fiddle" Tachycardia	↓ Vagal tone at the sinoatrial node

This patient with blurred vision, fever, altered mental status, flushed skin, and dry mucous membranes has **anticholinergic toxicity**, likely from encountering jimsonweed (*Datura stramonium*) while working in his yard. Jimsonweed contains large concentrations of the anticholinergic compounds **atropine**, **scopolamine**, and hyoscyamine. These agents competitively inhibit acetylcholine at the muscarinic acetylcholine receptor, leading to the classic toxidrome summarized above. Anticholinergic toxicity can be counteracted by increasing the concentration of acetylcholine in the synaptic cleft. **Physostigmine**, a cholinesterase inhibitor, increases acetylcholine levels by preventing its degradation by cholinesterase.

Explanation

Anticholinergic toxicity	
Symptom	**Mechanism**
"Hot as a hare" ↑ Body temperature	↓ Sweating leads to ↓ heat dissipation
"Dry as a bone" ↓ Secretions (eg, mucous membranes, sweat glands)	↓ Glandular secretion & smooth muscle contraction
"Red as a beet" Flushed skin	Superficial vasodilation from ↑ body heat
"Blind as a bat" Cycloplegia, mydriasis	Paralysis of ciliary muscle & iris sphincter
"Mad as a hatter" Altered mental status	Permeates blood-brain barrier & affects CNS pathways
"Full as a flask" Urinary retention Constipation	↓ Detrusor contraction & ↓ internal urethral sphincter relaxation ↓ Intestinal smooth muscle contraction
"Fast as a fiddle" Tachycardia	↓ Vagal tone at the sinoatrial node

This patient with blurred vision, fever, altered mental status, flushed skin, and dry mucous membranes has **anticholinergic toxicity**, likely from encountering jimsonweed (*Datura stramonium*) while working in his yard. Jimsonweed contains large concentrations of the anticholinergic compounds **atropine**, **scopolamine**, and hyoscyamine. These agents competitively inhibit acetylcholine at the muscarinic acetylcholine receptor,

This patient with blurred vision, fever, altered mental status, flushed skin, and dry mucous membranes has **anticholinergic toxicity**, likely from encountering jimsonweed (*Datura stramonium*) while working in his yard. Jimsonweed contains large concentrations of the anticholinergic compounds **atropine**, **scopolamine**, and hyoscyamine. These agents competitively inhibit acetylcholine at the muscarinic acetylcholine receptor, leading to the classic toxidrome summarized above. Anticholinergic toxicity can be counteracted by increasing the concentration of acetylcholine in the synaptic cleft. **Physostigmine**, a cholinesterase inhibitor, increases acetylcholine levels by preventing its degradation by cholinesterase.

(Choice A) Organophosphates are cholinesterase inhibitors that are commonly used as pesticides. Atropine can be used to counteract the effects of excess muscarinic stimulation (eg, increased salivation, miosis, bronchospasm, bradycardia). However, patients remain at risk of paralysis due to nicotinic overactivation, and so also require treatment with pralidoxime, a cholinesterase reactivating agent.

(Choices B and D) Benztropine is a centrally acting anticholinergic medication used for the treatment of idiopathic and drug-induced Parkinson disease. Haloperidol is a neuroleptic drug that blocks dopamine receptors in the central nervous system and is used to treat psychosis. These drugs have anticholinergic effects that would worsen this patient's symptoms.

(Choice C) Diazepam, a long-acting benzodiazepine, positively modulates $GABA_A$ action by increasing the frequency of chloride channel opening. It is used to treat seizures associated with atropine poisoning but does not affect muscarinic cholinergic receptors.

(Choice E) Metoprolol is a selective β1-adrenergic receptor antagonist. It is used to treat angina, acute coronary syndromes, heart failure, hypertension, and arrhythmias.

(Choices F and G) Morphine is an opioid pain medication that exerts its affects by stimulating opioid receptors in the brain. Naloxone is a competitive antagonist of these receptors used for opioid overdose. Morphine has some anticholinergic effects and may worsen symptoms whereas naloxone does not affect cholinergic receptors.

(Choice I) Thiamine (B_1) is a cofactor for multiple enzymes used in glucose metabolism. Patients who are chronically deficient (eg, due to alcoholism or malnutrition) can develop Wernicke-Korsakoff syndrome (ataxia, ophthalmoplegia, confusion).

Educational objective:
Anticholinergic agents (eg, atropine, scopolamine) competitively inhibit acetylcholine at the muscarinic acetylcholine receptor. The effects can be memorized with the mnemonic, "Blind as a bat, mad as a hatter, red as a beet, hot as a hare, dry as a bone, full as a flask, and fast as a fiddle," and can be reversed by cholinesterase inhibitors (physostigmine).

(Choice A) Organophosphates are cholinesterase inhibitors that are commonly used as pesticides. Atropine can be used to counteract the effects of excess muscarinic stimulation (eg, increased salivation, miosis, bronchospasm, bradycardia). However, patients remain at risk of paralysis due to nicotinic overactivation, and so also require treatment with pralidoxime, a cholinesterase reactivating agent.

(Choices B and D) Benztropine is a centrally acting anticholinergic medication used for the treatment of idiopathic and drug-induced Parkinson disease. Haloperidol is a neuroleptic drug that blocks dopamine receptors in the central nervous system and is used to treat psychosis. These drugs have anticholinergic effects that would worsen this patient's symptoms.

(Choice C) Diazepam, a long-acting benzodiazepine, positively modulates $GABA_A$ action by increasing the frequency of chloride channel opening. It is used to treat seizures associated with atropine poisoning but does not affect muscarinic cholinergic receptors.

(Choice E) Metoprolol is a selective β1-adrenergic receptor antagonist. It is used to treat angina, acute coronary syndromes, heart failure, hypertension, and arrhythmias.

(Choices F and G) Morphine is an opioid pain medication that exerts its affects by stimulating opioid receptors in the brain. Naloxone is a competitive antagonist of these receptors used for opioid overdose. Morphine has some anticholinergic effects and may worsen symptoms whereas naloxone does not affect cholinergic receptors.

(Choice I) Thiamine (B_1) is a cofactor for multiple enzymes used in glucose metabolism. Patients who are chronically deficient (eg, due to alcoholism or malnutrition) can develop Wernicke-Korsakoff syndrome (ataxia, ophthalmoplegia, confusion).

Educational objective:
Anticholinergic agents (eg, atropine, scopolamine) competitively inhibit acetylcholine at the muscarinic acetylcholine receptor. The effects can be memorized with the mnemonic, "Blind as a bat, mad as a hatter, red as a beet, hot as a hare, dry as a bone, full as a flask, and fast as a fiddle," and can be reversed by cholinesterase inhibitors (physostigmine).

Pharmacology	Nervous System	Anticholinergics
Subject	System	Topic

Copyright © UWorld. All rights reserved.

An 11-year-old boy is brought to the emergency department by ambulance after he briefly lost consciousness. The patient's mother found him on the kitchen floor shaking and jerking. She believes that he was out of her sight for only a few minutes. When asked about any other abnormal behaviors, she says that her son often stares into space and does not respond to questions during these episodes. The patient has no known medical conditions or history of recent illnesses. He is afebrile with normal vital signs. The patient seems sleepy but is oriented to time and place and has no abnormalities on physical examination. Several hours later, he is alert and says that he wants to go home. Which of the following agents is the best long-term treatment for this patient?

A. Carbamazepine
B. Ethosuximide
C. Gabapentin
D. Phenytoin
E. Valproic acid

Submit

An 11-year-old boy is brought to the emergency department by ambulance after he briefly lost consciousness. The patient's mother found him on the kitchen floor shaking and jerking. She believes that he was out of her sight for only a few minutes. When asked about any other abnormal behaviors, she says that her son often stares into space and does not respond to questions during these episodes. The patient has no known medical conditions or history of recent illnesses. He is afebrile with normal vital signs. The patient seems sleepy but is oriented to time and place and has no abnormalities on physical examination. Several hours later, he is alert and says that he wants to go home. Which of the following agents is the best long-term treatment for this patient?

- A. Carbamazepine (4%)
- B. Ethosuximide (46%)
- C. Gabapentin (0%)
- D. Phenytoin (4%)
- ✓ E. Valproic acid (43%)

Omitted
Correct answer
E

43%
Answered correctly

02 secs
Time Spent

03/02/2020
Last Updated

Explanation

Seizure type	Description	Preferred anticonvulsants
Focal onset (involves a single cerebral hemisphere at onset)		

Seizure type	Description	Preferred anticonvulsants
Focal onset (involves a single cerebral hemisphere at onset)		
Aware	• No loss of consciousness or postictal state • Motor, sensory, autonomic, or cognitive symptoms	• Carbamazepine* • Lamotrigine • Levetiracetam • Phenytoin*
Impaired awareness	• Appears awake but consciousness is altered (eg, blank stare) • Postictal state • May have automatisms (eg, lip smacking)	
Generalized onset (involves both hemispheres at onset)		
Tonic-clonic	• Loss of consciousness & postictal state • Diffuse muscle contraction of limbs (tonic) followed by rhythmic jerking (clonic)	• Levetiracetam • Valproic acid
Myoclonic	• No loss of consciousness or postictal state • Brief jerking movements	
Absence	• Brief episodes of altered consciousness (eg, blank stare) • May have automatisms • Usually no postictal state	• Ethosuxamide • Valproic acid

*Narrow-spectrum agents can also treat focal-onset seizures that evolve into bilateral tonic-clonic seizures.

This patient with frequent staring spells (ie, **absence seizures**) and an unprovoked **tonic-clonic seizure** most likely has undiagnosed juvenile absence epilepsy. Absence seizures are characterized by momentary lapses in consciousness (~10 seconds) associated with a classic 3-Hz spike-wave pattern on electroencephalogram. Younger children with absence seizures typically do not develop other seizure types; however, later onset (eg, age 10-12) of absence epilepsy is associated with an increased incidence of generalized onset tonic-clonic or myoclonic seizures.

Absence	• May have automatisms • Usually no postictal state	• Valproic acid

*Narrow-spectrum agents can also treat focal-onset seizures that evolve into bilateral tonic-clonic seizures.

This patient with frequent staring spells (ie, **absence seizures**) and an unprovoked **tonic-clonic seizure** most likely has undiagnosed juvenile absence epilepsy. Absence seizures are characterized by momentary lapses in consciousness (~10 seconds) associated with a classic 3-Hz spike-wave pattern on electroencephalogram. Younger children with absence seizures typically do not develop other seizure types; however, later onset (eg, age 10-12) of absence epilepsy is associated with an increased incidence of generalized onset tonic-clonic or myoclonic seizures.

Although a first-time unprovoked seizure may not require treatment, this patient has had multiple seizures, including both absence and tonic-clonic seizures. Ethosuximide is the preferred first-line agent for the treatment of isolated absence seizures; however, it does not suppress tonic-clonic seizures **(Choice B)**. Treatment with a **broad-spectrum** antiepileptic such as **valproic acid** is required in these patients because it is effective for both absence and tonic-clonic seizures.

(Choices A, C, and D) Carbamazepine, phenytoin, and gabapentin are narrow-spectrum antiepileptics that can be used to treat focal onset seizures (including focal onset seizures that progress to bilateral tonic-clonic seizures). However, they are not effective for treating generalized onset seizures (eg, absence, myoclonic) which can actually be worsened by treatment with carbamazepine or phenytoin.

Educational objective:
Older children with absence seizures may also develop generalized onset tonic-clonic or myoclonic seizures. Although ethosuximide is effective against isolated absence seizures, it is not effective for tonic-clonic seizures. Valproic acid is a broad-spectrum antiepileptic that treats both types of seizures.

References

- Ethosuximide, sodium valproate or lamotrigine for absence seizures in children and adolescents.

Pharmacology	Nervous System	Seizures
Subject	System	Topic

Copyright © UWorld. All rights reserved.

An elderly immigrant from the Middle East presents to your office complaining of numbness and tingling of his hands and feet. He was diagnosed with pulmonary tuberculosis several months ago and is currently receiving isoniazid and rifampin. Neurologic testing demonstrates sensory ataxia and decreased pain sensation in the distal extremities. This patient's condition is most likely caused by:

A. Immune-mediated demyelinization

B. Bacterial toxin-mediated axonal damage

C. Drug-mediated toxic neuron loss

D. Vitamin deficiency

E. Diabetic neuropathy

Submit

An elderly immigrant from the Middle East presents to your office complaining of numbness and tingling of his hands and feet. He was diagnosed with pulmonary tuberculosis several months ago and is currently receiving isoniazid and rifampin. Neurologic testing demonstrates sensory ataxia and decreased pain sensation in the distal extremities. This patient's condition is most likely caused by:

- A. Immune-mediated demyelinization (3%)
- B. Bacterial toxin-mediated axonal damage (2%)
- C. Drug-mediated toxic neuron loss (26%)
- ✓ D. Vitamin deficiency (66%)
- E. Diabetic neuropathy (1%)

Omitted
Correct answer
D

66%
Answered correctly

01 sec
Time Spent

02/03/2020
Last Updated

Explanation

Isoniazid is chemically similar to pyridoxine (vitamin B_6). Because of this similarity, isoniazid can compete with vitamin B_6 in the synthesis of multiple neurotransmitters (including GABA), resulting in defective end products. Isoniazid also increases the urinary excretion of pyridoxine, and a frank deficiency of this vitamin can eventually develop. Vitamin B_6 deficiency most commonly occurs in patients treated with isoniazid who are elderly, alcoholics, or who have other comorbidities (eg, kidney or liver dysfunction). When isoniazid neuropathy occurs, it usually clinically manifests as peripheral neuropathy. To prevent these adverse effects, supplemental vitamin B6 is typically prescribed in conjunction with isoniazid.

(Choice A) Immune-mediated demyelinization occurs in multiple sclerosis and the Guillain-Barre syndrome. These conditions are not associated

Isoniazid is chemically similar to pyridoxine (vitamin B_6). Because of this similarity, isoniazid can compete with vitamin B_6 in the synthesis of multiple neurotransmitters (including GABA), resulting in defective end products. Isoniazid also increases the urinary excretion of pyridoxine, and a frank deficiency of this vitamin can eventually develop. Vitamin B_6 deficiency most commonly occurs in patients treated with isoniazid who are elderly, alcoholics, or who have other comorbidities (eg, kidney or liver dysfunction). When isoniazid neuropathy occurs, it usually clinically manifests as peripheral neuropathy. To prevent these adverse effects, supplemental vitamin B6 is typically prescribed in conjunction with isoniazid.

(Choice A) Immune-mediated demyelinization occurs in multiple sclerosis and the Guillain-Barre syndrome. These conditions are not associated with antibiotic therapy of any kind.

(Choice B) Bacterial toxin-mediated axonal damage occurs in infections secondary to Corynebacterium diphtheriae, a microorganism that classically causes pseudomembranous pharyngitis. C. diphtheriae synthesizes a potent exotoxin associated with cardiac and neural toxicity.

(Choice C) Pyridoxine deficiency, not drug-mediated toxic neuron loss, is responsible for this patient's neuropathy. Drugs known to be directly toxic to nerves include the chemotherapeutic agents that inhibit microtubule formation (eg, vincristine and paclitaxel).

(Choice E) There is no evidence or clinical history suggestive of diabetic neuropathy in this patient. The primary cause of diabetic neuropathy is glucose-induced neural toxicity. High concentrations of glucose result in the formation of glycosylation products (eg, hemoglobin A1c) and the accumulation of sorbitol within the nerves, a phenomenon described as metabolic nerve damage.

Educational Objective:
Isoniazid is structurally similar to pyridoxine (vitamin B_6). As a result, this antibiotic increases the urinary excretion of pyridoxine – often causing a frank deficiency of vitamin B_6 — and competes for vitamin B_6-binding sites, leading to the defective synthesis of neurotransmitters like GABA. Isoniazid-induced neuropathy can usually be prevented with pyridoxine supplementation.

Pharmacology	Nervous System	Tuberculosis
Subject	System	Topic

Copyright © UWorld. All rights reserved.

A 3-year-old girl is brought to the office due to leg stiffness. Her mother reports that the patient is a clumsy walker and requires assistance to ambulate. The patient was born preterm and has delayed developmental skills. Physical examination shows increased knee and ankle reflexes and clonus at the ankles bilaterally. Muscle tone of the upper extremities and neck is also mildly increased. MRI of the brain reveals periventricular leukomalacia suggestive of cerebral palsy. An oral medication is prescribed that reduces the extremity stiffness. Which of the following CNS drug effects most likely resulted in this patient's improvement?

A. Activation of NMDA glutamate receptors

B. Agonistic activity at GABA receptors

C. Blockade of acetylcholine muscarinic receptors

D. Blockade of receptors for glycine

E. Increased dopaminergic activity

Submit

A 3-year-old girl is brought to the office due to leg stiffness. Her mother reports that the patient is a clumsy walker and requires assistance to ambulate. The patient was born preterm and has delayed developmental skills. Physical examination shows increased knee and ankle reflexes and clonus at the ankles bilaterally. Muscle tone of the upper extremities and neck is also mildly increased. MRI of the brain reveals periventricular leukomalacia suggestive of cerebral palsy. An oral medication is prescribed that reduces the extremity stiffness. Which of the following CNS drug effects most likely resulted in this patient's improvement?

- A. Activation of NMDA glutamate receptors (6%)
- ✓ B. Agonistic activity at GABA receptors (62%)
- C. Blockade of acetylcholine muscarinic receptors (13%)
- D. Blockade of receptors for glycine (6%)
- E. Increased dopaminergic activity (11%)

Omitted
Correct answer
B

62%
Answered correctly

02 secs
Time Spent

05/26/2020
Last Updated

Explanation

Explanation

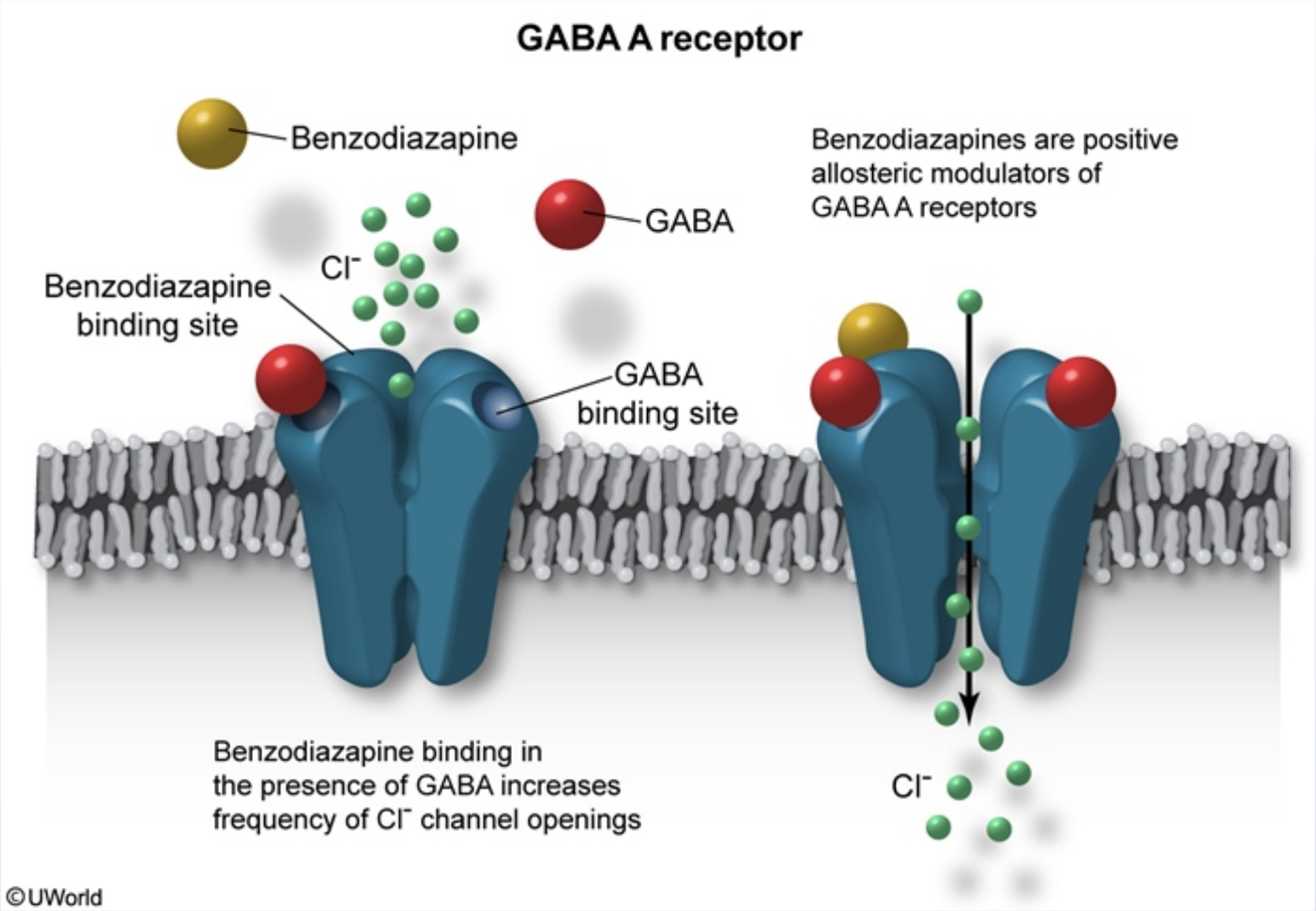

This patient has cerebral palsy, a heterogeneous condition characterized by permanent, nonprogressive motor dysfunction caused by damage to the developing brain. Certain subtypes (eg, spastic cerebral palsy) often manifest as delayed gross motor milestones and **spasticity** (eg, hypertonia, hyperreflexia). Spastic cerebral palsy may be caused by white matter necrosis (seen in this patient as periventricular leukomalacia), which leads to a **loss of descending inhibitory control** from the upper motor neurons. This results in muscle overactivity, leading to increased tone and hyperreflexia.

This patient has cerebral palsy, a heterogeneous condition characterized by permanent, nonprogressive motor dysfunction caused by damage to the developing brain. Certain subtypes (eg, spastic cerebral palsy) often manifest as delayed gross motor milestones and **spasticity** (eg, hypertonia, hyperreflexia). Spastic cerebral palsy may be caused by white matter necrosis (seen in this patient as periventricular leukomalacia), which leads to a **loss of descending inhibitory control** from the upper motor neurons. This results in muscle overactivity, leading to increased tone and hyperreflexia.

Enhancement of CNS inhibitory neurotransmitter activity can improve spasticity. **GABA** is the primary **inhibitory neurotransmitter** in the CNS and acts on two different receptors:

- **GABA A** receptor mediates a fast response to GABA because it is an ion-gated chloride channel. Activation of this receptor leads to rapid muscle relaxation and sedation. Its activity is enhanced by **benzodiazepines**, which can be used to treat spasticity.
- **GABA B** receptor mediates a slower response to GABA because it is mediated by a G protein–coupled receptor that opens potassium channels. It is agonized by **baclofen**, which can also be used to treat spasticity.

(Choice A) Glutamate is the primary excitatory CNS neurotransmitter; therefore, activation of NMDA glutamate receptors would result in increased excitation and lead to further increases in muscle tone.

(Choices C and E) Dopamine is a modulatory (rather than primarily excitatory or inhibitory) neurotransmitter that affects motor control. In patients with Parkinson disease who have a relative deficiency of dopamine in the substantia nigra, medications that increase dopaminergic activity (eg, levodopa) can improve muscle rigidity. In some patients, a relative excess of acetylcholine compared to dopamine has been implicated in the tremor or rigidity associated with Parkinson disease or drug-induced parkinsonism. In these patients, anticholinergic medications (eg, trihexyphenidyl) are sometimes used.

(Choice D) Glycine is an inhibitory neurotransmitter found primarily in the spinal cord rather than in the brain. Blockade of glycine receptors (eg, strychnine poisoning) leads to increased muscle contraction.

Educational objective:
Cerebral palsy results in spasticity (eg, hypertonia, hyperreflexia) due to a loss of descending inhibitory control. Medications used to enhance the activity of GABA, the primary inhibitory neurotransmitter of the CNS, can improve spasticity.

tone and hyperreflexia.

Enhancement of CNS inhibitory neurotransmitter activity can improve spasticity. **GABA** is the primary **inhibitory neurotransmitter** in the CNS and acts on two different receptors:

- **GABA A** receptor mediates a fast response to GABA because it is an ion-gated chloride channel. Activation of this receptor leads to rapid muscle relaxation and sedation. Its activity is enhanced by **benzodiazepines**, which can be used to treat spasticity.
- **GABA B** receptor mediates a slower response to GABA because it is mediated by a G protein–coupled receptor that opens potassium channels. It is agonized by **baclofen**, which can also be used to treat spasticity.

(Choice A) Glutamate is the primary excitatory CNS neurotransmitter; therefore, activation of NMDA glutamate receptors would result in increased excitation and lead to further increases in muscle tone.

(Choices C and E) Dopamine is a modulatory (rather than primarily excitatory or inhibitory) neurotransmitter that affects motor control. In patients with Parkinson disease who have a relative deficiency of dopamine in the substantia nigra, medications that increase dopaminergic activity (eg, levodopa) can improve muscle rigidity. In some patients, a relative excess of acetylcholine compared to dopamine has been implicated in the tremor or rigidity associated with Parkinson disease or drug-induced parkinsonism. In these patients, anticholinergic medications (eg, trihexyphenidyl) are sometimes used.

(Choice D) Glycine is an inhibitory neurotransmitter found primarily in the spinal cord rather than in the brain. Blockade of glycine receptors (eg, strychnine poisoning) leads to increased muscle contraction.

Educational objective:
Cerebral palsy results in spasticity (eg, hypertonia, hyperreflexia) due to a loss of descending inhibitory control. Medications used to enhance the activity of GABA, the primary inhibitory neurotransmitter of the CNS, can improve spasticity.

Pharmacology	Nervous System	Spasticity
Subject	System	Topic

Copyright © UWorld. All rights reserved.

A 48-year-old woman comes to the office due to lower extremity discomfort. The patient reports no pain but describes an uncomfortable sensation in her legs, particularly in the evening and at night. The symptoms are relieved by leg movements or walking. She reports no behavioral or mood changes. The patient intermittently experiences mild migraines, and during a recent episode, antiemetic therapy worsened the leg discomfort. She has no other medical conditions and does not use tobacco, alcohol, or illicit drugs. Vital signs are within normal limits, and physical examination shows no abnormalities. Blood cell counts, serum chemistry studies, and serum iron levels are within normal limits. Pharmacotherapy with which of the following mechanisms of action is most likely to relieve this patient's symptoms?

A. Beta-adrenergic antagonist

B. Dopamine receptor agonist

C. Muscarinic receptor antagonist

D. Opioid mu-receptor agonist

E. Selective serotonin reuptake inhibitor

Submit

A 48-year-old woman comes to the office due to lower extremity discomfort. The patient reports no pain but describes an uncomfortable sensation in her legs, particularly in the evening and at night. The symptoms are relieved by leg movements or walking. She reports no behavioral or mood changes. The patient intermittently experiences mild migraines, and during a recent episode, antiemetic therapy worsened the leg discomfort. She has no other medical conditions and does not use tobacco, alcohol, or illicit drugs. Vital signs are within normal limits, and physical examination shows no abnormalities. Blood cell counts, serum chemistry studies, and serum iron levels are within normal limits. Pharmacotherapy with which of the following mechanisms of action is most likely to relieve this patient's symptoms?

A. Beta-adrenergic antagonist (9%)
✓ B. Dopamine receptor agonist (57%)
C. Muscarinic receptor antagonist (7%)
D. Opioid mu-receptor agonist (4%)
E. Selective serotonin reuptake inhibitor (20%)

Omitted
Correct answer
B

57%
Answered correctly

01 sec
Time Spent

03/25/2020
Last Updated

Explanation

Restless leg syndrome	
Clinical features	Uncomfortable urge to move the legs with: • Unpleasant sensations in the legs

Restless leg syndrome	
Clinical features	Uncomfortable urge to move the legs with: • Unpleasant sensations in the legs • Onset with inactivity or at night • Relief with movement (eg, walking, stretching)
Causes	• Idiopathic • Iron deficiency • Uremia • Diabetes (especially with neuropathy)
Treatment	• Avoidance of aggravating factors (eg, alcohol, sleep deprivation) • Dopamine agonists (eg, pramipexole) • Gabapentin/pregabalin

This patient with vague lower extremity discomfort and an urge to move the legs that worsens at night has typical features of **restless legs syndrome (RLS)**. RLS is characterized by **uncomfortable sensations in the legs** that are often difficult to describe and associated with an **urge to move** the lower extremities. Symptoms are **relieved with movement** (eg, walking, stretching) and are typically worse at **night**. As a result, patients often develop sleep-onset insomnia.

The pathophysiology of RLS is incompletely understood but likely involves **CNS iron deficiency** (even in patients with normal serum iron levels) and **abnormalities in dopaminergic transmission**. Certain medications, including dopamine antagonists (eg, antipsychotics, certain antiemetics [metoclopramide]), first-generation antihistamines (eg, diphenhydramine), and antidepressants (eg, selective serotonin reuptake inhibitors, mirtazapine) are associated with worsening symptoms **(Choice E)**.

Treatment includes avoidance of aggravating medications, **iron replacement**, and **dopamine agonists** (eg, ropinirole, pramipexole) which are thought to modulate CNS dopaminergic transmission and are rapidly effective in most cases.

The pathophysiology of RLS is incompletely understood but likely involves **CNS iron deficiency** (even in patients with normal serum iron levels) and **abnormalities in dopaminergic transmission**. Certain medications, including dopamine antagonists (eg, antipsychotics, certain antiemetics [metoclopramide]), first-generation antihistamines (eg, diphenhydramine), and antidepressants (eg, selective serotonin reuptake inhibitors, mirtazapine) are associated with worsening symptoms **(Choice E)**.

Treatment includes avoidance of aggravating medications, **iron replacement**, and **dopamine agonists** (eg, ropinirole, pramipexole) which are thought to modulate CNS dopaminergic transmission and are rapidly effective in most cases.

(Choice A) Beta-adrenergic antagonists (eg, propranolol) are used for treating akathisia (ie, a strong urge to move), which occurs most commonly as a side effect of dopamine antagonists (eg, antipsychotic drugs). However, akathisia is not accompanied by an unpleasant sensation in the legs and does not follow a circadian rhythm.

(Choice C) Muscarinic antagonists (eg, benztropine) have been used for the treatment of dystonia, which is characterized by sustained muscle contractions usually associated with abnormal posturing (eg, torticollis).

(Choice D) Opioid mu-receptor agonists (eg, codeine) are occasionally used for treating refractory RLS, but carry significant risks (eg, sedation, abuse, respiratory depression).

Educational objective:
Restless legs syndrome is characterized by an uncomfortable sensation in the legs accompanied by an urge to move them; symptoms worsen with inactivity and at night and are temporarily relieved with movement. Dopamine agonists (eg, pramipexole, ropinirole) are the preferred therapy for persistent symptoms.

References

- Treatment of restless legs syndrome.

Pharmacology	Nervous System	Restless legs syndrome
Subject	System	Topic

Copyright © UWorld. All rights reserved.

A 67-year-old smoker comes to the office with a 2-week history of decreased vision in his right eye that he describes as "blurry" and "distorted." The patient has been having vision problems over the past year, and these have made it more difficult to drive and require that he use a bright light to read the newspaper. He has no history of diabetes mellitus or hypertension. The patient uses an albuterol inhaler for occasional wheezing and shortness of breath. Ophthalmologic examination of the right eye shows a grayish discoloration of the macula with areas of adjacent hemorrhage. Which of the following should be specifically targeted in treatment of this patient's condition?

A. CD20 lymphocyte glycoprotein

B. Epidermal growth factor receptor

C. Interleukin-2

D. Tumor necrosis factor-alpha

E. Vascular endothelial growth factor

Submit

A 67-year-old smoker comes to the office with a 2-week history of decreased vision in his right eye that he describes as "blurry" and "distorted." The patient has been having vision problems over the past year, and these have made it more difficult to drive and require that he use a bright light to read the newspaper. He has no history of diabetes mellitus or hypertension. The patient uses an albuterol inhaler for occasional wheezing and shortness of breath. Ophthalmologic examination of the right eye shows a grayish discoloration of the macula with areas of adjacent hemorrhage. Which of the following should be specifically targeted in treatment of this patient's condition?

A. CD20 lymphocyte glycoprotein (1%)

B. Epidermal growth factor receptor (6%)

C. Interleukin-2 (3%)

D. Tumor necrosis factor-alpha (6%)

✓ E. Vascular endothelial growth factor (82%)

Omitted
Correct answer
E

82%
Answered correctly

03 secs
Time Spent

04/12/2020
Last Updated

Explanation

This patient likely has **age-related macular degeneration (AMD)**, the leading cause of blindness in industrialized countries. AMD occurs in genetically predisposed individuals as a result of advancing age and environmental factors (eg, smoking) and is classified into dry and wet subtypes. **Dry AMD** is characterized by **gradual** vision loss in one or both eyes and can cause difficulty with driving/reading. The condition likely results from chronic oxidative damage to the retinal pigment epithelium and choriocapillaris, leading to subretinal inflammation with abnormal extracellular matrix formation (eg, confluent drusen, basement membrane thickening). These changes appear on funduscopy as subretinal drusen

Explanation

This patient likely has **age-related macular degeneration (AMD)**, the leading cause of blindness in industrialized countries. AMD occurs in genetically predisposed individuals as a result of advancing age and environmental factors (eg, smoking) and is classified into dry and wet subtypes. **Dry AMD** is characterized by **gradual** vision loss in one or both eyes and can cause difficulty with driving/reading. The condition likely results from chronic oxidative damage to the retinal pigment epithelium and choriocapillaris, leading to subretinal inflammation with abnormal extracellular matrix formation (eg, confluent drusen, basement membrane thickening). These changes appear on funduscopy as subretinal drusen deposits with pigment abnormalities.

Progressive extracellular matrix accumulation can eventually result in retinal hypoxia, which stimulates local vascular endothelial growth factor (VEGF) production and causes subretinal neovascularization with formation of leaky vessels. This condition is termed **wet AMD** and presents with **acute** vision loss (days to weeks) with **metamorphopsia** (distortion of straight lines). Funduscopy shows a grayish-green subretinal discoloration with adjacent fluid/hemorrhage.

Patients with dry or wet AMD may benefit from antioxidant vitamins and zinc, and smokers should receive **smoking cessation** counseling to prevent disease progression. Wet AMD usually requires specific treatment with **VEGF inhibitors** (eg, ranibizumab, bevacizumab).

(Choice A) Therapy against the CD20 glycoprotein on B cells (eg, the monoclonal antibody rituximab) is used to treat various lymphomas and active rheumatoid arthritis.

(Choice B) Epidermal growth factor receptor inhibitors (eg, erlotinib, gefitinib) are used to treat advanced non-small cell lung cancer.

(Choice C) Anti-interleukin-2 therapy is primarily used for immunosuppression in organ transplant patients and in conditions such as graft versus host disease.

(Choice D) Inhibitors of tumor necrosis factor-alpha are used in many inflammatory autoimmune conditions, such as rheumatoid arthritis, inflammatory bowel disease, and seronegative spondyloarthropathies.

Educational objective:
Wet age-related macular degeneration is characterized by retinal neovascularization due to increased vascular endothelial growth factor (VEGF) levels. Patients typically have acute vision loss and metamorphopsia with funduscopy showing a grayish-green subretinal membrane and/or subretinal hemorrhage. Treatment includes smoking cessation and VEGF inhibitor therapy (eg, ranibizumab, bevacizumab).

acute vision loss (days to weeks) with **metamorphopsia** (distortion of straight lines). Funduscopy shows a grayish-green subretinal discoloration with adjacent fluid/hemorrhage.

Patients with dry or wet AMD may benefit from antioxidant vitamins and zinc, and smokers should receive **smoking cessation** counseling to prevent disease progression. Wet AMD usually requires specific treatment with **VEGF inhibitors** (eg, ranibizumab, bevacizumab).

(Choice A) Therapy against the CD20 glycoprotein on B cells (eg, the monoclonal antibody rituximab) is used to treat various lymphomas and active rheumatoid arthritis.

(Choice B) Epidermal growth factor receptor inhibitors (eg, erlotinib, gefitinib) are used to treat advanced non-small cell lung cancer.

(Choice C) Anti-interleukin-2 therapy is primarily used for immunosuppression in organ transplant patients and in conditions such as graft versus host disease.

(Choice D) Inhibitors of tumor necrosis factor-alpha are used in many inflammatory autoimmune conditions, such as rheumatoid arthritis, inflammatory bowel disease, and seronegative spondyloarthropathies.

Educational objective:
Wet age-related macular degeneration is characterized by retinal neovascularization due to increased vascular endothelial growth factor (VEGF) levels. Patients typically have acute vision loss and metamorphopsia with funduscopy showing a grayish-green subretinal membrane and/or subretinal hemorrhage. Treatment includes smoking cessation and VEGF inhibitor therapy (eg, ranibizumab, bevacizumab).

References

- Anti-VEGF compounds in the treatment of neovascular age related macular degeneration
- Long-term follow-up of vascular endothelial growth factor inhibitor therapy for neovascular age-related macular degeneration.
- Current concepts in the pathogenesis of age-related macular degeneration.

Pharmacology	Ophthalmology	Macular degeneration
Subject	System	Topic

Copyright © UWorld. All rights reserved.

Which of the following should be specifically targeted in treatment of this patient's condition?

Exhibit Display

AMD, Calcified Drusen (#1) AMD, Exudative

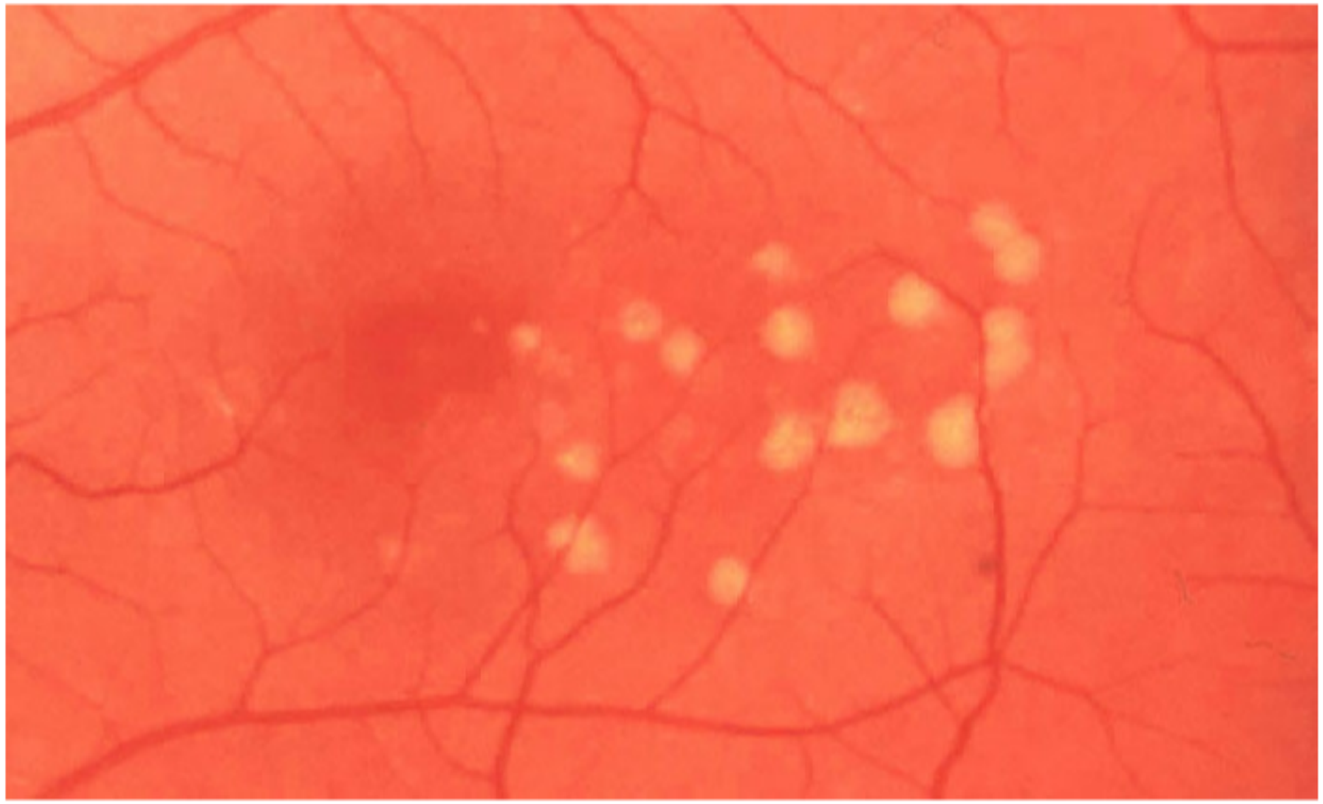

Zoom In | Zoom Out | Reset | Add To New Card | Existing Card

with adjacent fluid/hemorrhage.

Which of the following should be specifically targeted in treatment of this patient's condition?

Exhibit Display

AMD, Calcified Drusen (#1) AMD, Exudative

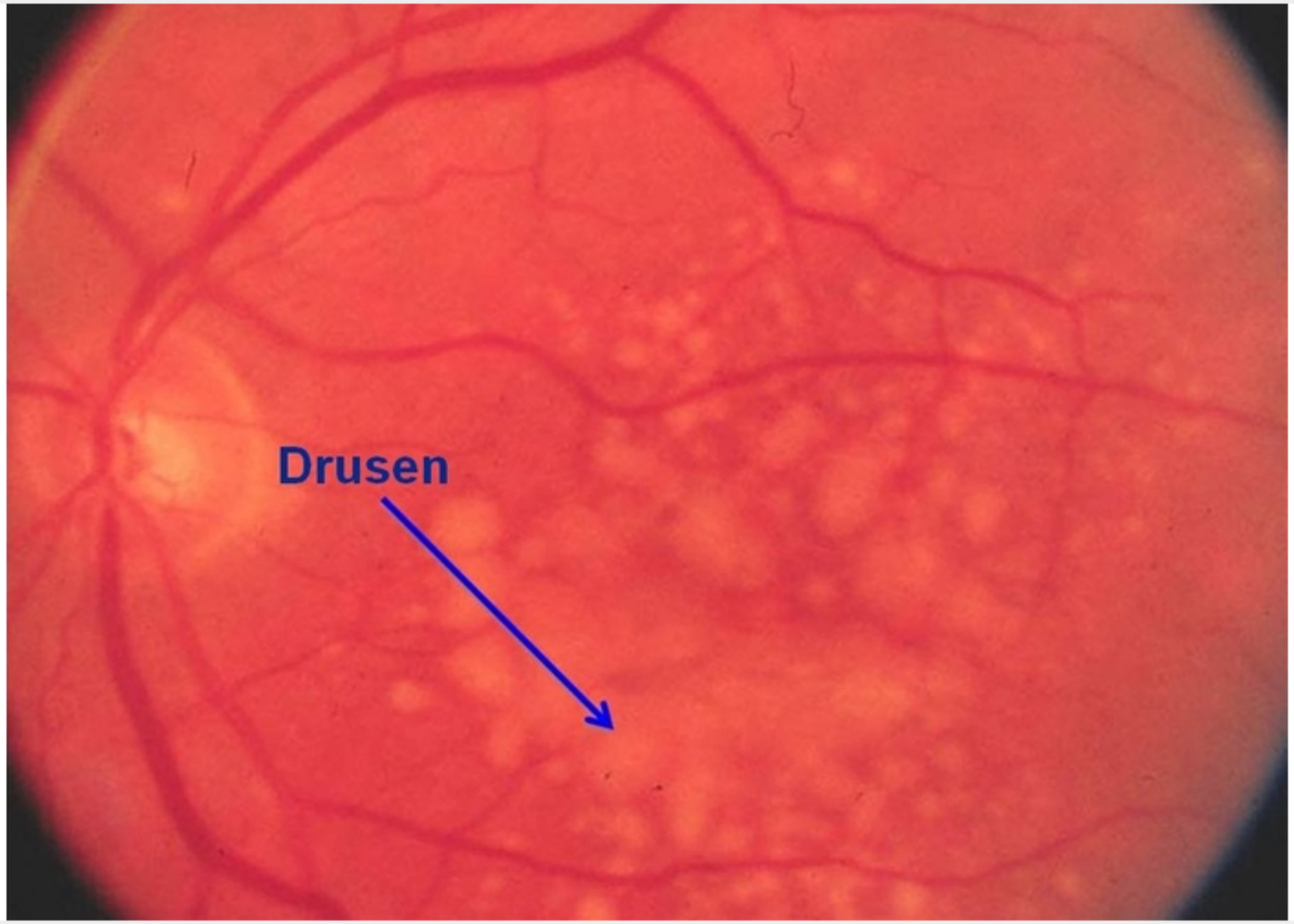

Zoom In | Zoom Out | Reset | Add To New Card | Existing Card

with adjacent fluid/hemorrhage.

deposits with pigment abnormalities.

Exhibit Display

Zoom In Zoom Out Reset Add To New Card | Existing Card

Pharmacology Ophthalmology Macular degeneration

(VEGF) production and causes subretinal neovascularization with formation of leaky vessels. This condition is termed **wet AMD** and presents with **acute** vision loss (days to weeks) with **metamorphopsia** (distortion of straight lines). Funduscopy shows a grayish-green subretinal discoloration with adjacent fluid/hemorrhage.

Patients with dry or wet AMD may benefit from antioxidant vitamins and zinc, and smokers should receive **smoking cessation** counseling to prevent disease progression. Wet AMD usually requires specific treatment with **VEGF inhibitors** (eg, ranibizumab, bevacizumab).

(Choice A) Therapy against the CD20 glycoprotein on B cells (eg, the monoclonal antibody rituximab) is used to treat various lymphomas and active rheumatoid arthritis.

(Choice B) Epidermal growth factor receptor inhibitors (eg, erlotinib, gefitinib) are used to treat advanced non-small cell lung cancer.

(Choice C) Anti-interleukin-2 therapy is primarily used for immunosuppression in organ transplant patients and in conditions such as graft versus host disease.

(Choice D) Inhibitors of tumor necrosis factor-alpha are used in many inflammatory autoimmune conditions, such as rheumatoid arthritis, inflammatory bowel disease, and seronegative spondyloarthropathies.

Educational objective:
Wet age-related macular degeneration is characterized by retinal neovascularization due to increased vascular endothelial growth factor (VEGF) levels. Patients typically have acute vision loss and metamorphopsia with funduscopy showing a grayish-green subretinal membrane and/or subretinal hemorrhage. Treatment includes smoking cessation and VEGF inhibitor therapy (eg, ranibizumab, bevacizumab).

References

- Anti-VEGF compounds in the treatment of neovascular age related macular degeneration
- Long-term follow-up of vascular endothelial growth factor inhibitor therapy for neovascular age-related macular degeneration.
- Current concepts in the pathogenesis of age-related macular degeneration.

Pharmacology	Ophthalmology	Macular degeneration
Subject	System	Topic

A 64-year-old African American woman is brought to the clinic by her husband due to a fall. She was walking in her living room when she tripped over an electrical cord. The patient has had several other ground-level falls in the last 6 months but has had no significant injuries. She also gave up driving a year ago following a near-miss motor vehicle accident. Past medical history is notable for hypertension and type 2 diabetes mellitus, for which she takes appropriate medications. Mental status and neurologic examinations are normal. Ophthalmic examination reveals reduced vision in her peripheral visual fields bilaterally and an elevated intraocular pressure. After discussion of treatment options, the patient is initiated on timolol ophthalmic drops. Which of the following structures is the most likely target of this medication?

A. Ciliary epithelium

B. Ciliary muscle

C. Lens

D. Pupil sphincter

E. Trabecular meshwork

Submit

A 64-year-old African American woman is brought to the clinic by her husband due to a fall. She was walking in her living room when she tripped over an electrical cord. The patient has had several other ground-level falls in the last 6 months but has had no significant injuries. She also gave up driving a year ago following a near-miss motor vehicle accident. Past medical history is notable for hypertension and type 2 diabetes mellitus, for which she takes appropriate medications. Mental status and neurologic examinations are normal. Ophthalmic examination reveals reduced vision in her peripheral visual fields bilaterally and an elevated intraocular pressure. After discussion of treatment options, the patient is initiated on timolol ophthalmic drops. Which of the following structures is the most likely target of this medication?

- ✓ A. Ciliary epithelium (42%)
- B. Ciliary muscle (27%)
- C. Lens (0%)
- D. Pupil sphincter (7%)
- E. Trabecular meshwork (20%)

Omitted
Correct answer
A

42%
Answered correctly

02 secs
Time Spent

04/02/2020
Last Updated

Explanation

Glaucoma medications

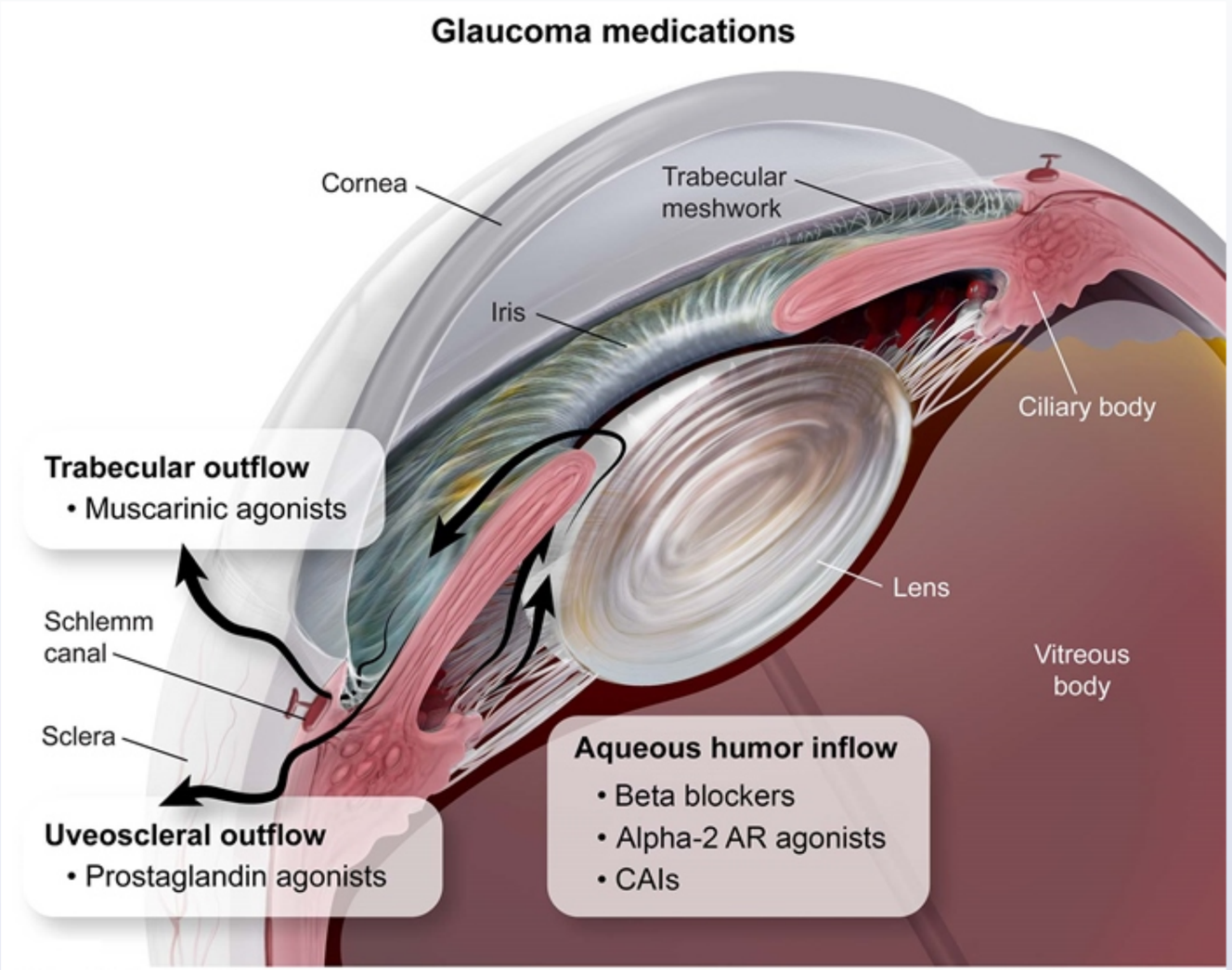

Alpha-2 AR agonists = alpha-2 adrenergic receptor agonists; **CAIs** = carbonic anhydrase inhibitors.

©UWorld

This patient with chronic, progressive loss of peripheral vision has typical features of **open-angle glaucoma**. Glaucoma is a type of **optic**

This patient with chronic, progressive loss of peripheral vision has typical features of **open-angle glaucoma**. Glaucoma is a type of **optic neuropathy** characterized by atrophy of the optic nerve head. It is more common with advancing age and is especially common in certain ethnicities (eg, African Americans). Glaucoma is usually associated with elevated intraocular pressure (IOP) due to increased production or decreased outflow of aqueous humor. **Aqueous humor** is produced by the epithelial cells of the ciliary body. It is secreted into the posterior eye chamber and transferred through the pupil into the anterior eye chamber. The anterior chamber angle (iridocorneal angle) contains a trabecular meshwork through which the aqueous humor diffuses into Schlemm's canal (scleral venous sinus) and subsequently into episcleral and conjunctival veins.

Diagnostic features of glaucoma include elevated IOP and abnormal visual field testing with decreased peripheral vision. Funduscopic examination will show an increased cup-to-disc ratio due to loss of ganglion cell axons. The goal of treatment in glaucoma is to decrease IOP with drugs that either decrease the production of aqueous humor or increase its outflow. Timolol and other nonselective beta blockers work by diminishing the secretion of aqueous humor by the ciliary epithelium.

(Choices B, C, D, and E) The intraocular muscles of the eye, including the ciliary muscle and pupillary sphincter of the iris, receive parasympathetic innervation from cholinergic fibers of the oculomotor nerve (cranial nerve III). Cholinergic agonists (eg, pilocarpine) cause miosis by promoting contraction of the sphincter of the iris. This causes the anterior chamber angle to become wider and makes the trabecular meshwork more accessible to outflow of aqueous humor. Cholinergic agonists also promote ciliary muscle contraction, causing the lens to become more convex.

Educational objective:
Open-angle glaucoma is characterized by progressive loss of peripheral vision from elevated intraocular pressure. Timolol and other nonselective beta blockers work by diminishing the secretion of aqueous humor by the ciliary epithelium. Acetazolamide, a carbonic anhydrase inhibitor, also decreases aqueous humor secretion by the ciliary epithelium. Prostaglandin F2α (eg, latanoprost, travoprost) and cholinomimetics (eg, pilocarpine, carbachol) decrease intraocular pressure by increasing the outflow of aqueous humor.

Pharmacology	Ophthalmology	Glaucoma
Subject	System	Topic

Copyright © UWorld. All rights reserved.

This patient with chronic, progressive loss of peripheral vision has typical features of **open-angle glaucoma**. Glaucoma is a type of **optic**

Exhibit Display

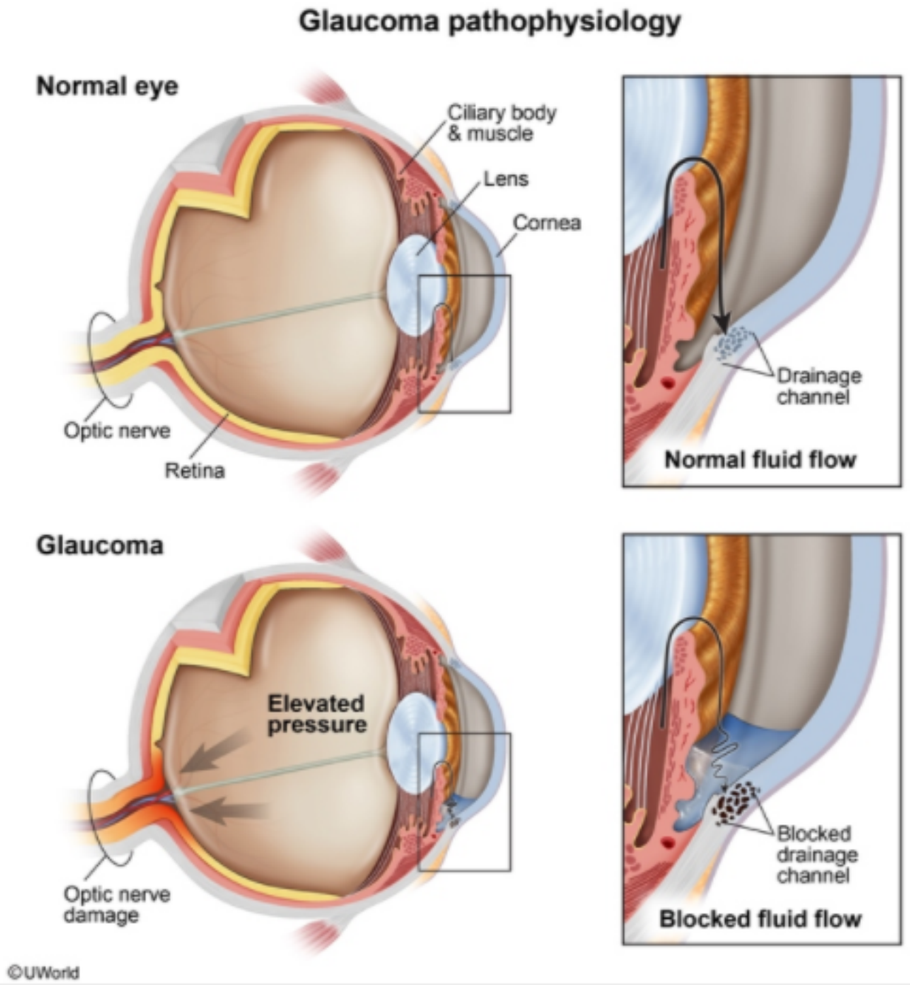

Zoom In | Zoom Out | Reset | Add To New Card | Existing Card

This patient with chronic, progressive loss of peripheral vision has typical features of **open-angle glaucoma**. Glaucoma is a type of **optic**

Exhibit Display

Optic disc in glaucoma

Normal	Open-angle glaucoma
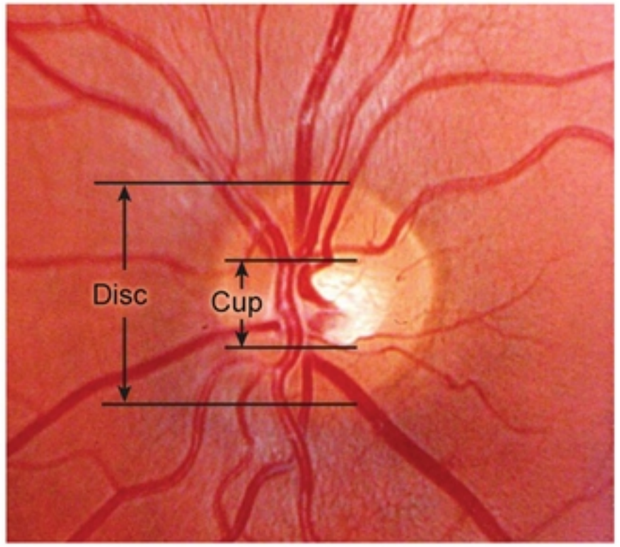	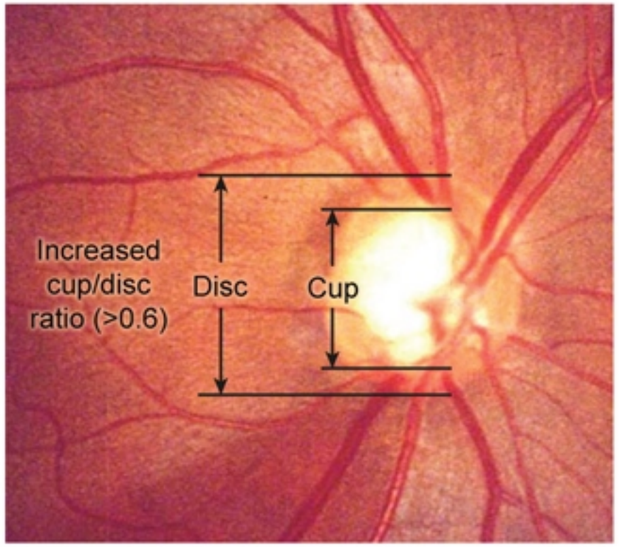
• Cup/disc ratio <0.5 • Clear disc rim	• Enlarged cup with cup/disc ratio >0.6 • Increase in cup size over time • Thinning of disc rim • Pale disc (optic nerve atrophy)

©UWorld

Zoom In | Zoom Out | Reset | Add To New Card | Existing Card

A 62-year-old woman comes to the emergency department due to acute eye pain. She has a history of seasonal allergies and developed itchy, watery, red eyes after working outdoors in her garden. The patient used over-the-counter eye drops to treat her allergy symptoms, and several hours later, she began experiencing severe right eye pain and headache. On examination, the right eye appears red with a hazy cornea and dilated pupil that responds poorly to light. Palpation of the globes reveals notable firmness on the right compared to the left. Visual acuity in the affected eye is severely diminished. Tonometry reveals elevated intraocular pressure. Which of the following medications was most likely used by this patient?

A. Alpha-adrenergic agonist

B. Beta blocker

C. Mast cell stabilizer

D. Nonsteroidal anti-inflammatory drug

E. Prostaglandin analogue

Submit

A 62-year-old woman comes to the emergency department due to acute eye pain. She has a history of seasonal allergies and developed itchy, watery, red eyes after working outdoors in her garden. The patient used over-the-counter eye drops to treat her allergy symptoms, and several hours later, she began experiencing severe right eye pain and headache. On examination, the right eye appears red with a hazy cornea and dilated pupil that responds poorly to light. Palpation of the globes reveals notable firmness on the right compared to the left. Visual acuity in the affected eye is severely diminished. Tonometry reveals elevated intraocular pressure. Which of the following medications was most likely used by this patient?

- ✓ A. Alpha-adrenergic agonist (70%)
- B. Beta blocker (8%)
- C. Mast cell stabilizer (5%)
- D. Nonsteroidal anti-inflammatory drug (6%)
- E. Prostaglandin analogue (9%)

Omitted
Correct answer
A

70%
Answered correctly

02 secs
Time Spent

02/16/2020
Last Updated

Explanation

Angle-closure glaucoma

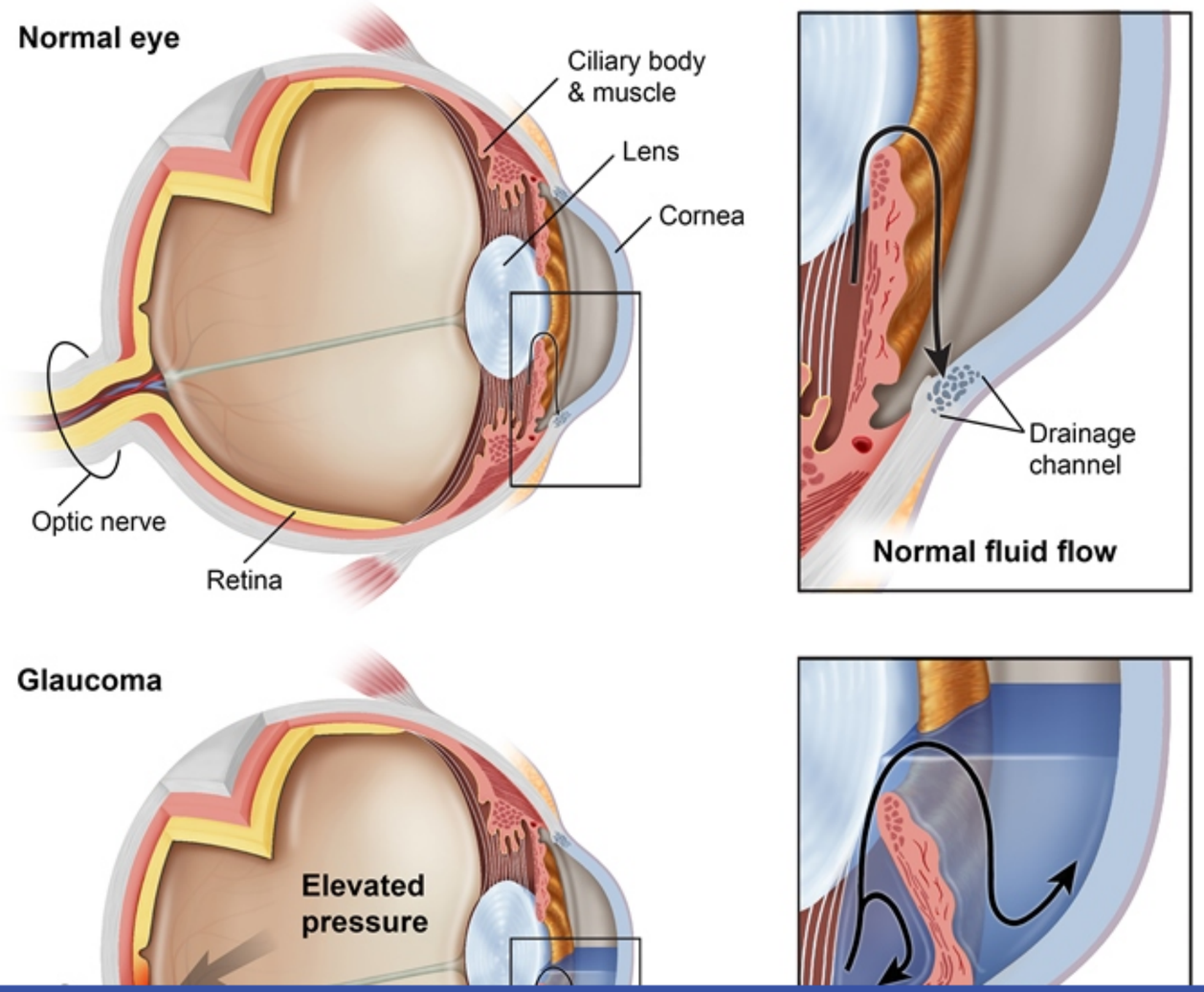

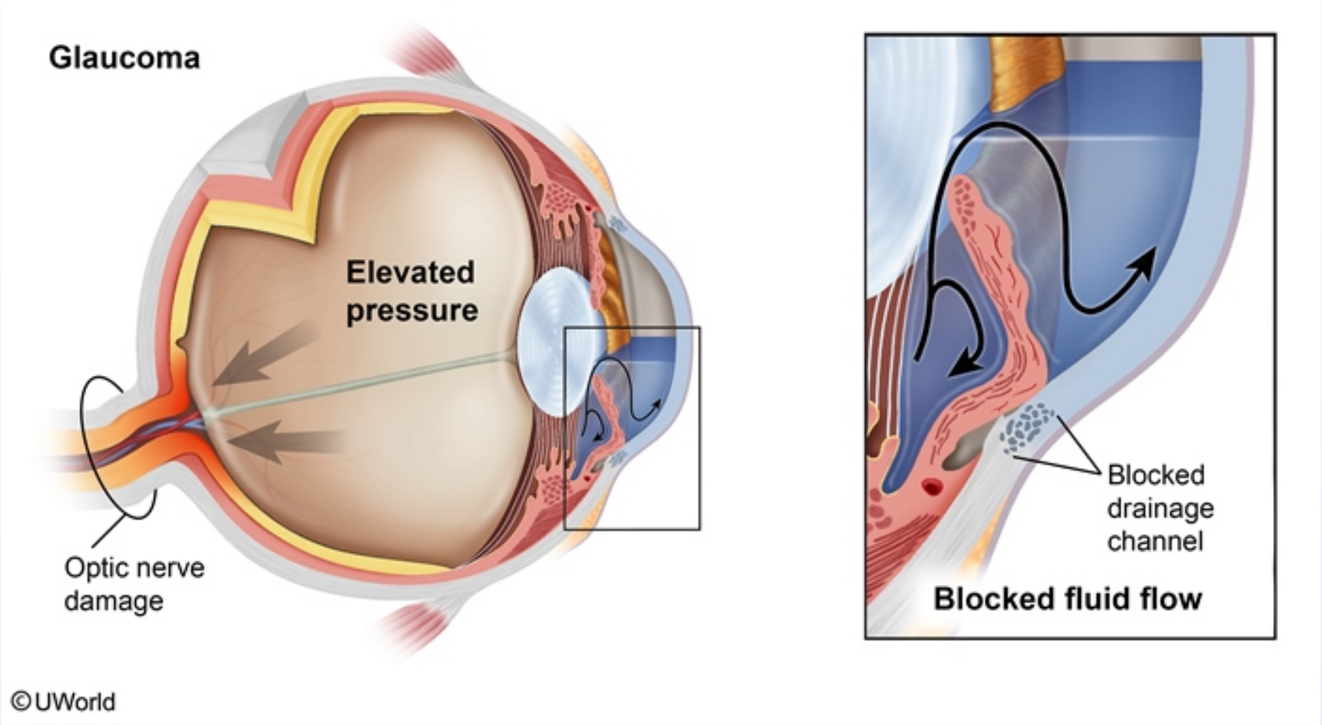

This patient is presenting with **angle-closure glaucoma** (ACG) that was precipitated by use of over-the-counter eye drops. ACG typically occurs in patients with a predisposing narrow chamber angle and develops when the normal drainage pathway of aqueous humor becomes blocked.

Aqueous humor is produced by the ciliary body and flows from the posterior chamber of the eye through the pupil into the anterior chamber and out of the eye via the trabecular network. In susceptible individuals, dilation of the pupil causes the iris to press against the anterior surface of the lens. This limits flow of aqueous humor through the pupil, causing the iris to bulge forward. The corresponding reduction (closing) of the iridocorneal angle blocks drainage of aqueous humor through the trabecular meshwork.

Acute ACG may be precipitated by topical and systemic medications that cause **pupillary dilation**, such as **alpha-adrenergic agonists** (eg, naphazoline) and drugs with strong **anticholinergic** effects (eg, tricyclic antidepressants, antihistamines). Acute blockage results in a rapid rise in intraocular pressure that typically causes **severe eye pain**, **conjunctival injection**, and **corneal edema** (haziness). If not corrected, the elevated pressure can damage the optic nerve and cause permanent vision impairment.

This patient is presenting with **angle-closure glaucoma** (ACG) that was precipitated by use of over-the-counter eye drops. ACG typically occurs in patients with a predisposing narrow chamber angle and develops when the normal drainage pathway of aqueous humor becomes blocked.

Aqueous humor is produced by the ciliary body and flows from the posterior chamber of the eye through the pupil into the anterior chamber and out of the eye via the trabecular network. In susceptible individuals, dilation of the pupil causes the iris to press against the anterior surface of the lens. This limits flow of aqueous humor through the pupil, causing the iris to bulge forward. The corresponding reduction (closing) of the iridocorneal angle blocks drainage of aqueous humor through the trabecular meshwork.

Acute ACG may be precipitated by topical and systemic medications that cause **pupillary dilation**, such as **alpha-adrenergic agonists** (eg, naphazoline) and drugs with strong **anticholinergic** effects (eg, tricyclic antidepressants, antihistamines). Acute blockage results in a rapid rise in intraocular pressure that typically causes **severe eye pain**, **conjunctival injection**, and **corneal edema** (haziness). If not corrected, the elevated pressure can damage the optic nerve and cause permanent vision impairment.

(Choice B) Topical beta blockers (eg, timolol) are used to treat open-angle glaucoma. They work by both reducing the production of aqueous humor and increasing its outflow from the trabecular network.

(Choices C and D) Topical mast cell stabilizers (eg, cromolyn, nedocromil) and nonsteroidal anti-inflammatory drugs (eg, ketorolac) are used in the treatment of allergic conjunctivitis, but they are not associated with ACG.

(Choice E) Prostaglandin analogues such as latanoprost increase aqueous outflow from the trabecular network and are used in the treatment of open-angle glaucoma.

Educational objective:
Acute angle-closure glaucoma occurs when the space between the cornea and iris is narrowed, limiting the flow of aqueous humor out of the anterior chamber and raising pressure in the eye. Medications that cause pupillary dilation (eg, alpha-adrenergic agonists, anticholinergics) can trigger acute angle-closure glaucoma.

References

- The pathophysiology and treatment of glaucoma: a review.

Pharmacology	Ophthalmology	Glaucoma
Subject	System	Topic

A 6-year-old asthmatic has the finding shown in the image below on routine examination.

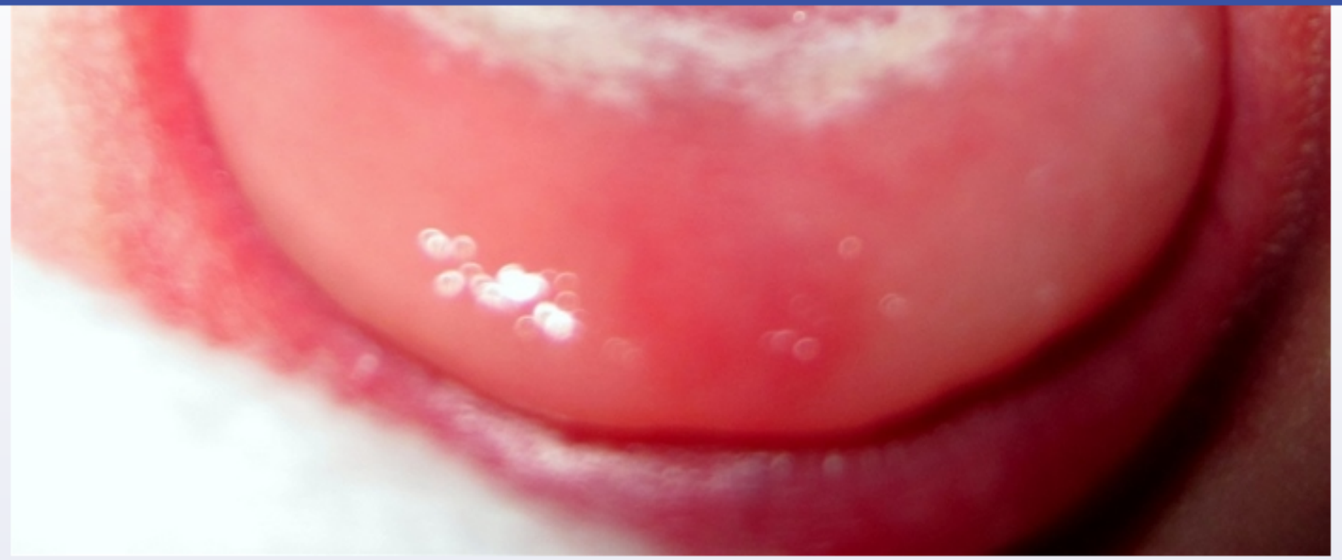

Which of the following is the most appropriate pharmacotherapy for the lesions on this patient's oral mucosa?

- A. Acyclovir
- B. Amphotericin-B
- C. Griseofulvin
- D. Nystatin
- E. Penicillin
- F. Terbinafine

Submit

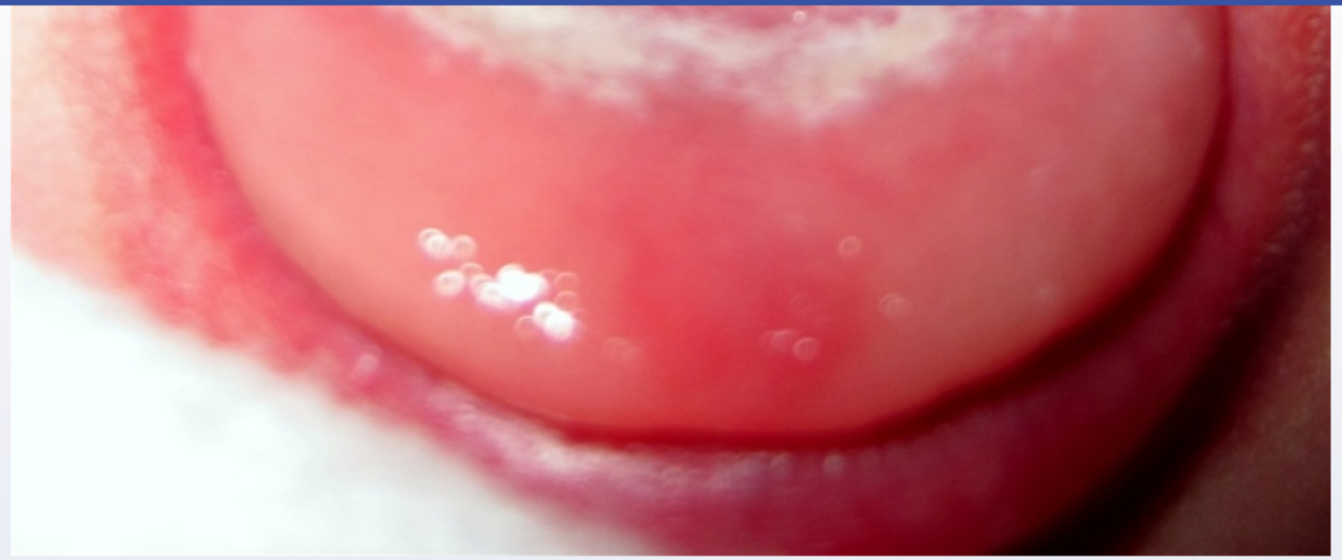

Which of the following is the most appropriate pharmacotherapy for the lesions on this patient's oral mucosa?

- A. Acyclovir (1%)
- B. Amphotericin-B (12%)
- C. Griseofulvin (4%)
- ✓ D. Nystatin (77%)
- E. Penicillin (0%)
- F. Terbinafine (2%)

Omitted
Correct answer

77%
Answered correctly

04 secs
Time Spent

05/20/2020
Last Updated

The thick white patches seen on this patient's tongue are indicative of oral thrush (oropharyngeal candidiasis). Thrush is a common variant of localized infection with *Candida* fungi. Oral thrush is common in young infants due to immaturity of the newborn immune system. In older children and adults, it is associated with immunosuppression and frequently occurs in patients with HIV infection, diabetes mellitus, and cancer. Asthma patients who take oral or inhaled steroids are also at risk for candidiasis. Systemic antibiotic therapy and dentures are other predisposing factors.

In immunocompetent patients, localized candidiasis is treated with topical antifungal medications. Nystatin is a polyene antifungal with a mechanism of action similar to amphotericin B. It binds to ergosterol molecules in the fungal cell membrane, causing pores and leakage of fungal cell contents. Nystatin is not absorbed from the gastrointestinal tract. It is administered as an oral agent ("swish and swallow") for oropharyngeal candidiasis.

(Choice A) Acyclovir is an antiviral drug effective against herpes simplex virus (1 and 2) and varicella zoster virus. It is a nucleoside analog that is converted into acyclo-GTP in infected cells, which inhibits viral DNA polymerase.

(Choice B) Amphotericin B is a polyene antifungal similar to nystatin used for systemic mycoses. It is administered intravenously and never used for simple mucocutaneous infections due to many toxic side effects.

(Choice C) Griseofulvin inhibits fungal cell mitosis at metaphase. It is indicated for the treatment of dermatophytoses, not candidiasis.

(Choice E) Penicillins are β-lactam antibiotics that inhibit the formation of peptidoglycan cross-links in bacterial cell walls.

(Choice F) Terbinafine is an allylamine antifungal that accumulates in the skin, nails, and adipose tissue. It is used to treat dermatophytosis (onychomycoses), not candidiasis.

Educational objective:
Nystatin is a polyene antifungal and the drug of choice for oropharyngeal candidiasis in patients without advanced immunodeficiency. It acts by binding to ergosterol in the fungal cell membrane, causing the formation of pores and leakage of fungal cell contents. Nystatin is not absorbed from the gastrointestinal tract and is administered as an oral "swish and swallow" agent.

Pharmacology	Ear, Nose & Throat (ENT)	Mucocutaneous candidiasis
Subject	System	Topic

localized infection with *Candida* fungi. Oral thrush is common in young infants due to immaturity of the newborn immune system. In older children and adults, it is associated with immunosuppression and frequently occurs in patients with HIV infection, diabetes mellitus, and cancer. Asthma patients who take oral or inhaled steroids are also at risk for candidiasis. Systemic antibiotic therapy and dentures are other predisposing factors.

In immunocompetent patients, localized candidiasis is treated with topical antifungal medications. Nystatin is a polyene antifungal with a mechanism of action similar to amphotericin B. It binds to ergosterol molecules in the fungal cell membrane, causing pores and leakage of fungal cell contents. Nystatin is not absorbed from the gastrointestinal tract. It is administered as an oral agent ("swish and swallow") for oropharyngeal candidiasis.

(Choice A) Acyclovir is an antiviral drug effective against herpes simplex virus (1 and 2) and varicella zoster virus. It is a nucleoside analog that is converted into acyclo-GTP in infected cells, which inhibits viral DNA polymerase.

(Choice B) Amphotericin B is a polyene antifungal similar to nystatin used for systemic mycoses. It is administered intravenously and never used for simple mucocutaneous infections due to many toxic side effects.

(Choice C) Griseofulvin inhibits fungal cell mitosis at metaphase. It is indicated for the treatment of dermatophytoses, not candidiasis.

(Choice E) Penicillins are β-lactam antibiotics that inhibit the formation of peptidoglycan cross-links in bacterial cell walls.

(Choice F) Terbinafine is an allylamine antifungal that accumulates in the skin, nails, and adipose tissue. It is used to treat dermatophytosis (onychomycoses), not candidiasis.

Educational objective:
Nystatin is a polyene antifungal and the drug of choice for oropharyngeal candidiasis in patients without advanced immunodeficiency. It acts by binding to ergosterol in the fungal cell membrane, causing the formation of pores and leakage of fungal cell contents. Nystatin is not absorbed from the gastrointestinal tract and is administered as an oral "swish and swallow" agent.

Pharmacology	Ear, Nose & Throat (ENT)	Mucocutaneous candidiasis
Subject	System	Topic

Copyright © UWorld. All rights reserved.

A 58-year-old airline captain comes to the office after he was found to have abnormal vision testing during a pilot medical certification examination. The patient feels well and has no ocular symptoms. Vision testing shows normal visual acuity but moderate loss of peripheral vision in both eyes. Results of the funduscopic examination are shown in the image below.

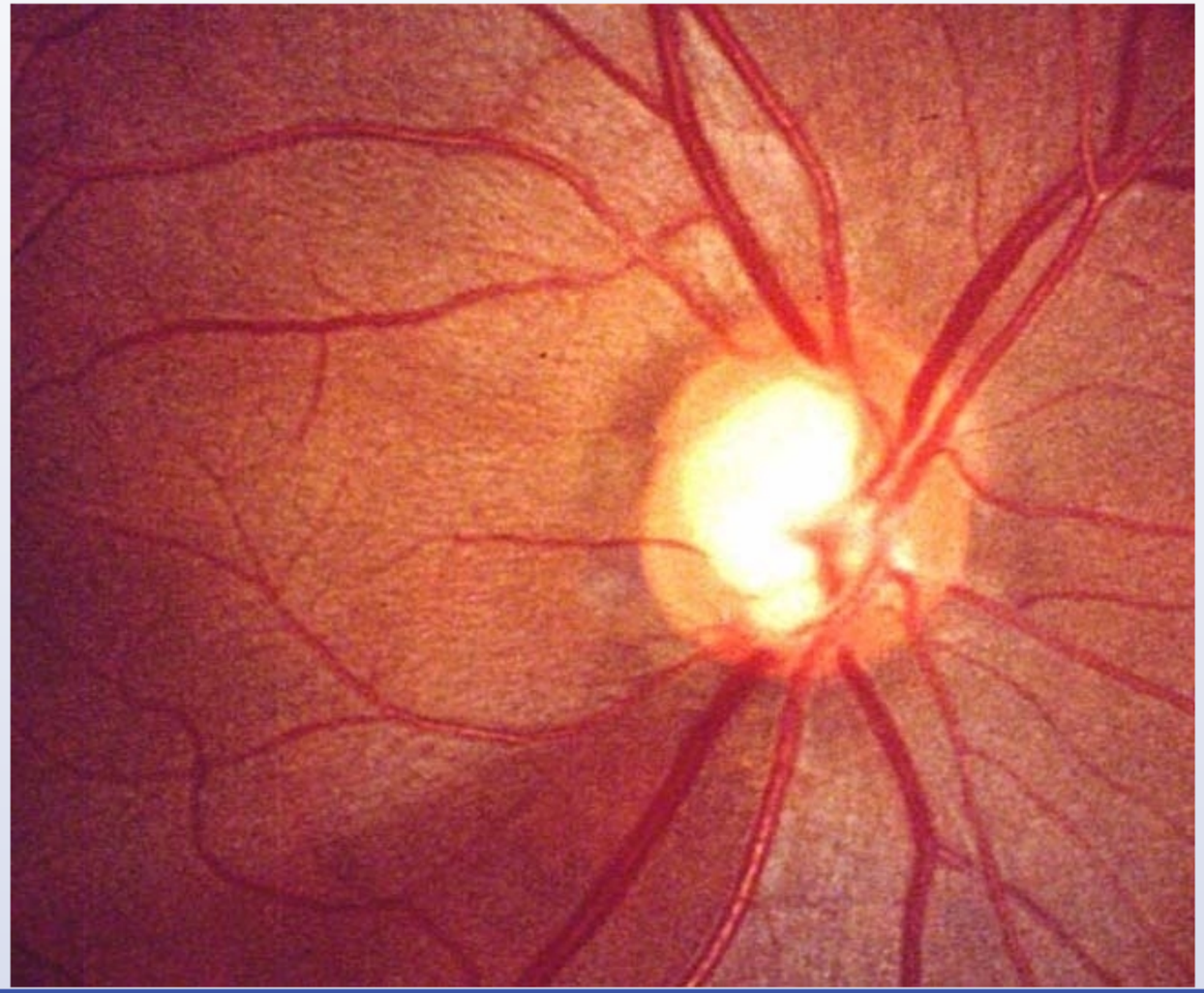

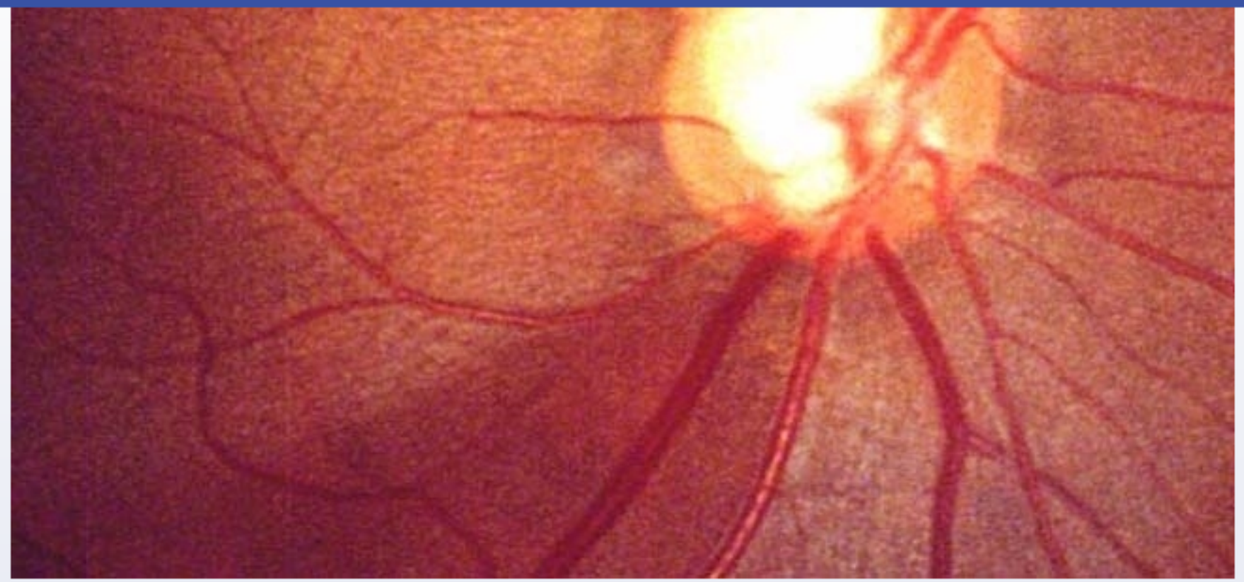

Other neurologic and cardiopulmonary examination findings are unremarkable. He is started on latanoprost eyedrops. The medication is most likely to improve this patient's condition through which of the following mechanisms?

A. Decreased bicarbonate formation in ciliary body

B. Decreased formation of abnormal blood vessels in retina

C. Decreased secretion of aqueous humor

D. Increased outflow of aqueous humor

E. Vasoconstriction in ciliary body

Submit

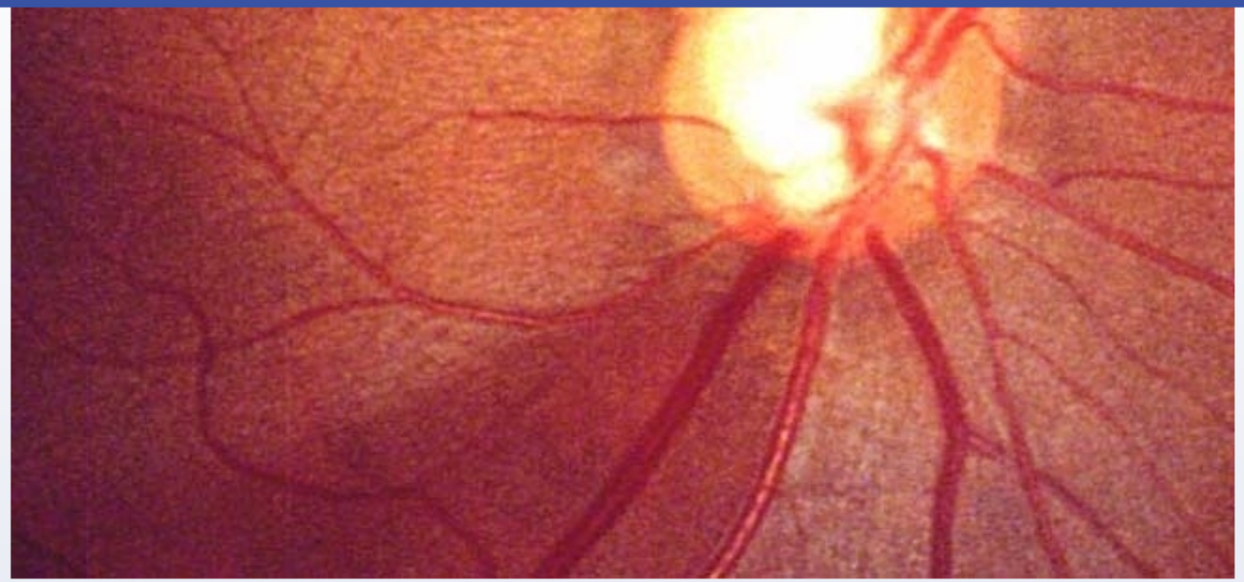

Other neurologic and cardiopulmonary examination findings are unremarkable. He is started on latanoprost eyedrops. The medication is most likely to improve this patient's condition through which of the following mechanisms?

A. Decreased bicarbonate formation in ciliary body (2%)

B. Decreased formation of abnormal blood vessels in retina (10%)

C. Decreased secretion of aqueous humor (21%)

✓ D. Increased outflow of aqueous humor (61%)

E. Vasoconstriction in ciliary body (4%)

Omitted
Correct answer

61%
Answered correctly

05 secs
Time Spent

04/02/2020
Last Updated

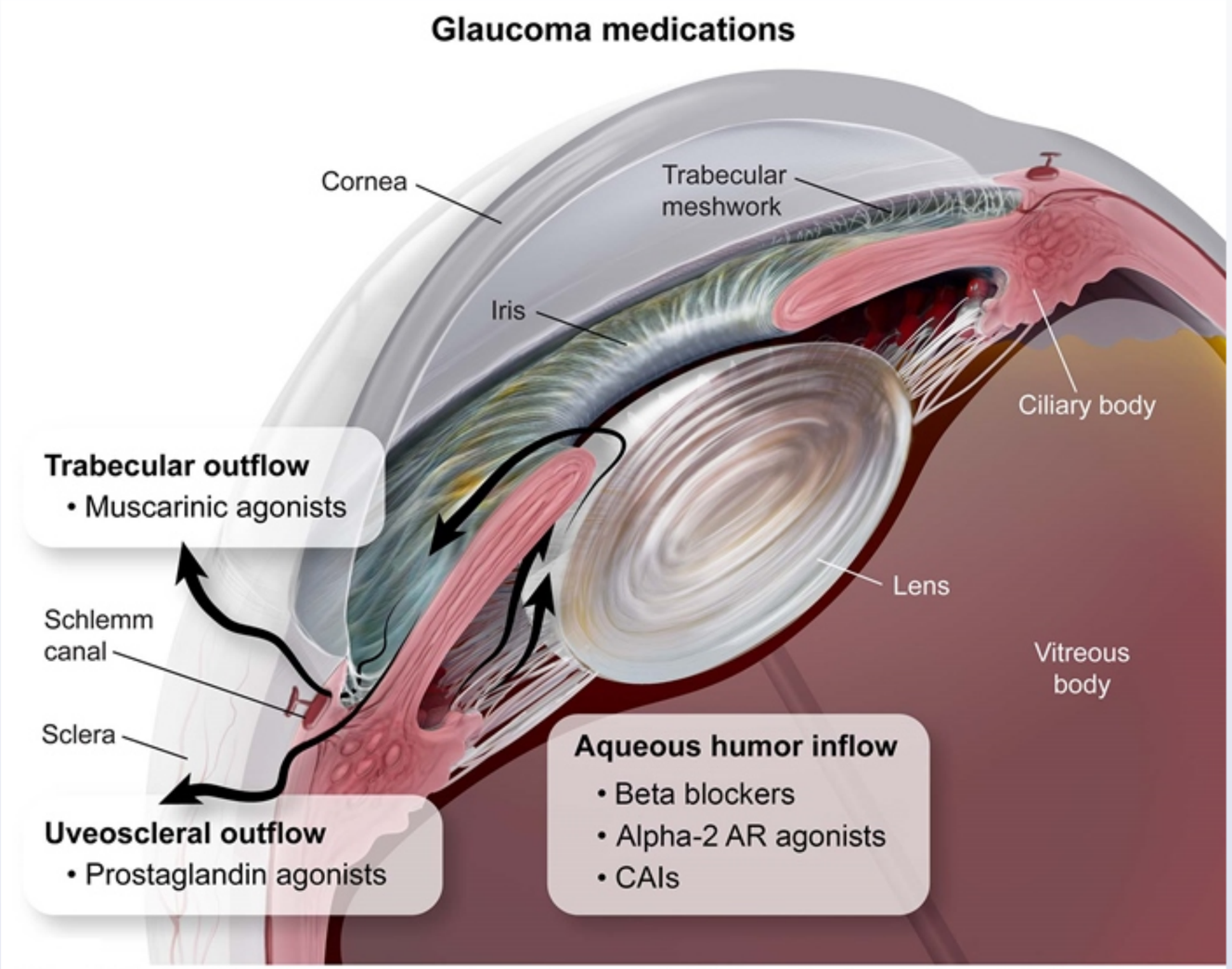

Alpha-2 AR agonists = alpha-2 adrenergic receptor agonists; **CAIs** = carbonic anhydrase inhibitors.

©UWorld

Aqueous humor is secreted by epithelial cells of the ciliary body into the posterior eye chamber. The fluid then flows through the pupil into the

©UWorld

Aqueous humor is secreted by epithelial cells of the ciliary body into the posterior eye chamber. The fluid then flows through the pupil into the anterior chamber to the iridocorneal angle. Here, it diffuses through a trabecular network into Schlemm's canal (scleral venous sinus) and subsequently drains into episcleral and conjunctival veins. A small amount of aqueous can also diffuse through the ciliary muscle and adjacent sclera (uveoscleral pathway).

Open-angle glaucoma is characterized by **increased intraocular pressure** due to increased secretion or decreased outflow of aqueous humor. It is a form of optic neuropathy and causes progressive loss of ganglion cell axons, which may be visualized as a pale optic disc and enlarged optic cup (compared to normal retina). Symptoms evolve over decades, with progressive loss of **peripheral visual fields**.

Glaucoma is managed with agents that either decrease production or increase outflow of aqueous humor. Latanoprost is a topical **prostaglandin** used in the treatment of glaucoma. It is applied as a prodrug and converted to the active form by esterases in the cornea. Prostaglandins are the preferred first-line agents for the treatment of glaucoma, and although the exact mechanism of action is uncertain, they have been found to decrease the collagen content in the uveoscleral outflow pathway and **increase outflow** of aqueous humor. They are also known to cause increased pigmentation in the iris and eyelashes.

(Choices A, C, and E) Carbonic anhydrase inhibitors (eg, dorzolamide) decrease formation of bicarbonate in the ciliary body, leading to decreased sodium and fluid transport and subsequently decreased production of aqueous humor. Alpha-adrenergic agonists (eg, brimonidine) inhibit production of aqueous humor due to vasoconstriction in the ciliary body. Beta blockers (eg, timolol) also decrease production of aqueous humor. Prostaglandins do not affect production of aqueous humor but are often used in combination with these other agents.

(Choice B) Increased formation of new blood vessels at the optic disc is the characteristic feature of proliferative diabetic retinopathy. Strict control of diabetes will reduce the risk of diabetic retinopathy, but it is not affected by topical prostaglandins.

Educational objective:
Glaucoma is a form of optic neuropathy characterized by increased intraocular pressure associated with increased production or decreased outflow of aqueous humor. Topical prostaglandins (eg, latanoprost) increase outflow of aqueous via the uveoscleral pathway and are the preferred treatment for open-angle glaucoma.

References

- Latanoprost ophthalmic solution in the treatment of open angle glaucoma or raised intraocular pressure: a review.

©UWorld

Exhibit Display

Glaucomatous optic atrophy (moderate)

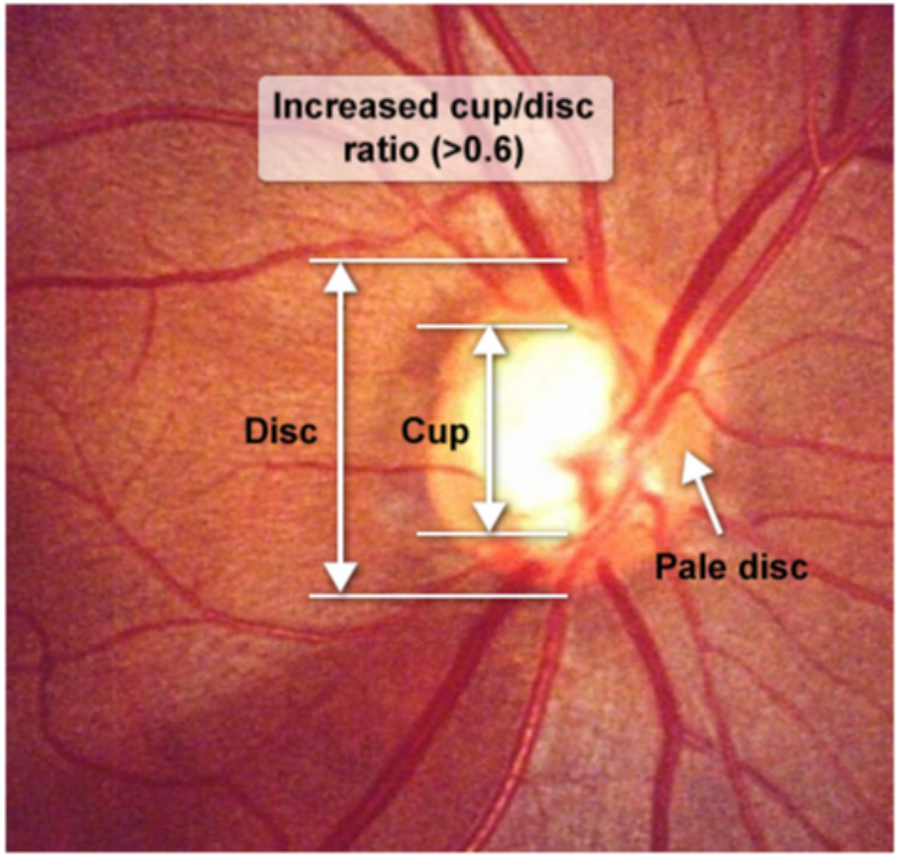

©UWorld

Zoom In | Zoom Out | Reset | Add To New Card | Existing Card

- Latanoprost ophthalmic solution in the treatment of open angle glaucoma or raised intraocular pressure: a review.

©UWorld

Exhibit Display

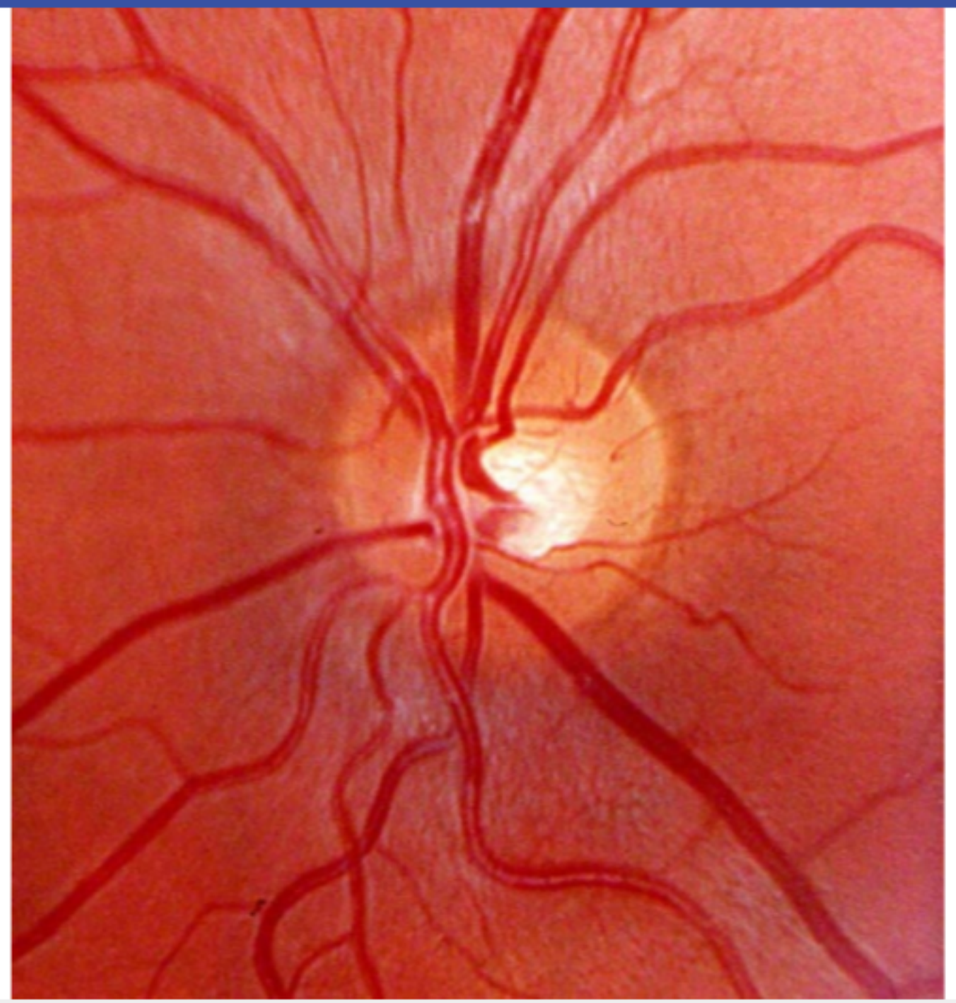

Zoom In | Zoom Out | Reset | Add To New Card | Existing Card

- Latanoprost ophthalmic solution in the treatment of open angle glaucoma or raised intraocular pressure: a review.

Open-angle glaucoma is characterized by **increased intraocular pressure** due to increased secretion or decreased outflow of aqueous humor. It is a form of optic neuropathy and causes progressive loss of ganglion cell axons, which may be visualized as a pale optic disc and enlarged optic cup (compared to normal retina). Symptoms evolve over decades, with progressive loss of **peripheral visual fields**.

Glaucoma is managed with agents that either decrease production or increase outflow of aqueous humor. Latanoprost is a topical **prostaglandin** used in the treatment of glaucoma. It is applied as a prodrug and converted to the active form by esterases in the cornea. Prostaglandins are the preferred first-line agents for the treatment of glaucoma, and although the exact mechanism of action is uncertain, they have been found to decrease the collagen content in the uveoscleral outflow pathway and **increase outflow** of aqueous humor. They are also known to cause increased pigmentation in the iris and eyelashes.

(Choices A, C, and E) Carbonic anhydrase inhibitors (eg, dorzolamide) decrease formation of bicarbonate in the ciliary body, leading to decreased sodium and fluid transport and subsequently decreased production of aqueous humor. Alpha-adrenergic agonists (eg, brimonidine) inhibit production of aqueous humor due to vasoconstriction in the ciliary body. Beta blockers (eg, timolol) also decrease production of aqueous humor. Prostaglandins do not affect production of aqueous humor but are often used in combination with these other agents.

(Choice B) Increased formation of new blood vessels at the optic disc is the characteristic feature of proliferative diabetic retinopathy. Strict control of diabetes will reduce the risk of diabetic retinopathy, but it is not affected by topical prostaglandins.

Educational objective:
Glaucoma is a form of optic neuropathy characterized by increased intraocular pressure associated with increased production or decreased outflow of aqueous humor. Topical prostaglandins (eg, latanoprost) increase outflow of aqueous via the uveoscleral pathway and are the preferred treatment for open-angle glaucoma.

References

- Latanoprost ophthalmic solution in the treatment of open angle glaucoma or raised intraocular pressure: a review.

Pharmacology	Ophthalmology	Glaucoma
Subject	System	Topic

Copyright © UWorld. All rights reserved.

A 35-year-old man comes to the physician because of a 2-week history of nasal congestion. He has used a topical decongestant every few hours since his symptoms began. He experienced relief for almost 1 week, but then his nasal congestion returned. The patient has a history of allergic rhinitis and has had episodes of rhinorrhea in the past, but none of them lasted longer than a few days. He denies fever, throat pain, headaches, cough, and lymph node enlargement. Aside from his allergic rhinitis, the patient has no other medical problems. Physical examination shows nasal mucosa that appears edematous and red with a few areas of punctate bleeding. The remainder of the examination reveals no abnormalities. Which of the following is the most appropriate next step in the management of this patient?

A. Stop the decongestant

B. Switch to ephedrine

C. Add oral corticosteroids

D. Add antihistamines

E. Start antibiotics

Submit

A 35-year-old man comes to the physician because of a 2-week history of nasal congestion. He has used a topical decongestant every few hours since his symptoms began. He experienced relief for almost 1 week, but then his nasal congestion returned. The patient has a history of allergic rhinitis and has had episodes of rhinorrhea in the past, but none of them lasted longer than a few days. He denies fever, throat pain, headaches, cough, and lymph node enlargement. Aside from his allergic rhinitis, the patient has no other medical problems. Physical examination shows nasal mucosa that appears edematous and red with a few areas of punctate bleeding. The remainder of the examination reveals no abnormalities. Which of the following is the most appropriate next step in the management of this patient?

- ✓ A. Stop the decongestant (67%)
- B. Switch to ephedrine (8%)
- C. Add oral corticosteroids (5%)
- D. Add antihistamines (15%)
- E. Start antibiotics (2%)

Omitted
Correct answer
A

67%
Answered correctly

02 secs
Time Spent

05/25/2020
Last Updated

Explanation

Vasoconstriction by α-adrenergic agonists is prominent in the vessels of the nasal mucosa, making these medications effective decongestants. Phenylephrine, xylometazoline, and oxymetazoline are used as topical preparations for the treatment of allergic rhinitis and common cold associated congestion and rhinitis.

These medications, however, are characterized by rapidly declining effect after a few days of use. This phenomenon is called tachyphylaxis. It

Vasoconstriction by α-adrenergic agonists is prominent in the vessels of the nasal mucosa, making these medications effective decongestants. Phenylephrine, xylometazoline, and oxymetazoline are used as topical preparations for the treatment of allergic rhinitis and common cold associated congestion and rhinitis.

These medications, however, are characterized by rapidly declining effect after a few days of use. This phenomenon is called tachyphylaxis. It occurs because of decreased production of endogenous norepinephrine from the nerve terminals due to a negative feedback mechanism, resulting in relative vasodilation (ie, removal of normal vasoconstrictive tone) and subsequent edema and congestion. This leads to exacerbation of the nasal congestion symptoms. Rebound rhinorrhea (ie, rhinitis medicamentosa) is described as nasal congestion without cough, sneezing, or postnasal drip. Rhinorrhea may or may not be present (note the paradox in naming). Rebound rhinorrhea is associated with the use of topical decongestants for ≥ 3 days. The use of adrenergic agonists should be stopped to allow the restoration of normal norepinephrine feedback pathways.

Another medication associated with the phenomenon of tachyphylaxis is nitroglycerine. The decrease in its effect is explained by the diminished release of NO from the target cells. Drug-free intervals of 8–10 hours should be maintained during the use of nitroglycerine to prevent tachyphylaxis.

(Choice B) Ephedrine is an indirect-acting adrenergic agonist used as a decongestant. Like the other adrenergic medications, it causes tachyphylaxis after a few days of treatment. A switch to ephedrine would not improve this patient's rebound rhinorrhea.

(Choice C) This patient has been excessively using a decongestant; if he discontinues it and experiences excessive withdrawal symptoms, a short-term course of topical corticosteroids can be considered for symptom control. However, oral corticosteroids would not be indicated.

(Choice D) Antihistamines are used for the treatment of allergic rhinitis, but they are not effective in treating rebound rhinorrhea.

(Choice E) Antibiotics are effective in the treatment of certain bacterial infections. They are not used in the treatment of rebound rhinorrhea.

Educational objective:
Topical preparations of α-adrenergic agonists cause vasoconstriction of the nasal mucosa vessels and are used as decongestants. Overuse of these drugs causes negative feedback, resulting in decreased norepinephrine synthesis and release from nerve endings, which diminishes their effect (ie, tachyphylaxis).

References

postnasal drip. Rhinorrhea may or may not be present (note the paradox in naming). Rebound rhinorrhea is associated with the use of topical decongestants for ≥ 3 days. The use of adrenergic agonists should be stopped to allow the restoration of normal norepinephrine feedback pathways.

Another medication associated with the phenomenon of tachyphylaxis is nitroglycerine. The decrease in its effect is explained by the diminished release of NO from the target cells. Drug-free intervals of 8–10 hours should be maintained during the use of nitroglycerine to prevent tachyphylaxis.

(Choice B) Ephedrine is an indirect-acting adrenergic agonist used as a decongestant. Like the other adrenergic medications, it causes tachyphylaxis after a few days of treatment. A switch to ephedrine would not improve this patient's rebound rhinorrhea.

(Choice C) This patient has been excessively using a decongestant; if he discontinues it and experiences excessive withdrawal symptoms, a short-term course of topical corticosteroids can be considered for symptom control. However, oral corticosteroids would not be indicated.

(Choice D) Antihistamines are used for the treatment of allergic rhinitis, but they are not effective in treating rebound rhinorrhea.

(Choice E) Antibiotics are effective in the treatment of certain bacterial infections. They are not used in the treatment of rebound rhinorrhea.

Educational objective:
Topical preparations of α-adrenergic agonists cause vasoconstriction of the nasal mucosa vessels and are used as decongestants. Overuse of these drugs causes negative feedback, resulting in decreased norepinephrine synthesis and release from nerve endings, which diminishes their effect (ie, tachyphylaxis).

References

- Rhinitis medicamentosa.
- Diagnosing rhinitis: allergic vs. nonallergic.

Pharmacology	Ear, Nose & Throat (ENT)	Nonallergic rhinitis
Subject	System	Topic

Copyright © UWorld. All rights reserved.

A 58-year-old man comes to the emergency department due to vision disturbances. Over the past several weeks, the patient has had intermittent episodes in which he sees everything tinted with blue. His vision returned to normal within a few hours each time. When he woke up today, vision in the left eye was blurry. He has had no eye pain, conjunctival redness, or headache. The patient has tingling and numbness in the feet due to diabetic neuropathy, which is unchanged, and reports no other focal weakness or sensory loss. Medical history is notable for hypertension, type 2 diabetes mellitus, hyperlipidemia, and erectile dysfunction. Vital signs are within normal limits. Physical examination shows an afferent pupillary defect, decreased visual acuity, and optic disc edema in the left eye. Discontinuing which of the following medications may improve this patient's vision?

- A. Amitriptyline
- B. Atorvastatin
- C. Canagliflozin
- D. Metformin
- E. Ramipril
- F. Sildenafil

Submit

A 58-year-old man comes to the emergency department due to vision disturbances. Over the past several weeks, the patient has had intermittent episodes in which he sees everything tinted with blue. His vision returned to normal within a few hours each time. When he woke up today, vision in the left eye was blurry. He has had no eye pain, conjunctival redness, or headache. The patient has tingling and numbness in the feet due to diabetic neuropathy, which is unchanged, and reports no other focal weakness or sensory loss. Medical history is notable for hypertension, type 2 diabetes mellitus, hyperlipidemia, and erectile dysfunction. Vital signs are within normal limits. Physical examination shows an afferent pupillary defect, decreased visual acuity, and optic disc edema in the left eye. Discontinuing which of the following medications may improve this patient's vision?

- A. Amitriptyline
- B. Atorvastatin
- C. Canagliflozin
- D. Metformin
- E. Ramipril
- F. Sildenafil

Submit

Adverse effects of phosphodiesterase 5 inhibitors	
Cardiovascular	• **Hypotension** (especially with nitrates, alpha blockers)
Ocular	• Blue discoloration of vision • Nonarteritic anterior ischemic optic neuropathy
Genitourinary	• **Priapism**
Other	• Flushing • Headache • Hearing loss

Normal male erectile function involves interplay between psychological and physical stimulation and the vascular, neurologic, and hormonal systems. On a vascular level, penile erection is induced by increased blood flow to the corpora cavernosa and corpus spongiosum accompanied by decreased outflow. Endothelial factors required for erection include formation of nitric oxide, which induces formation of cyclic GMP (cGMP), which in turn mediates vascular smooth muscle relaxation. cGMP is inactivated by cGMP phosphodiesterase (PDE) (ie, PDE5), which cleaves cGMP and terminates penile erection.

PDE5 inhibitors (eg, sildenafil, tadalafil) are widely used, first-line agents for treatment of **erectile dysfunction** (ED). PDE5 inhibitors increase activity of cGMP in the penile corpora, leading to greater and more prolonged tumescence in men with ED.

However, PDE5 inhibitors can also inhibit PDE6 in the retina, which is involved in color vision. Patients experience this effect as a transient **bluish discoloration** to vision. Less common ocular effects of PDE5 inhibitors include **nonarteritic anterior ischemic optic neuropathy**, which presents with sudden monocular vision loss associated with an afferent pupillary defect, decreased visual acuity, and optic disc edema.

(Choice A) The anticholinergic effects of tricyclic antidepressants (eg, amitriptyline) can cause dry eye, blurred vision, and triggering of angle-closure glaucoma (ie, ocular pain, headache, unilateral vision loss). Discoloration of vision is not typical.

(Choice B) Important side effects of statins (eg, atorvastatin) include myopathy and hepatic toxicity. Statins may have a small effect on the risk of cataract but otherwise have few ocular manifestations.

(Choice C) Sodium glucose cotransporter 2 inhibitors (eg, canagliflozin) induce increased renal excretion of glucose and water. Most of the side

activity of cGMP in the penile corpora, leading to greater and more prolonged tumescence in men with ED.

However, PDE5 inhibitors can also inhibit PDE6 in the retina, which is involved in color vision. Patients experience this effect as a transient **bluish discoloration** to vision. Less common ocular effects of PDE5 inhibitors include **nonarteritic anterior ischemic optic neuropathy**, which presents with sudden monocular vision loss associated with an afferent pupillary defect, decreased visual acuity, and optic disc edema.

(Choice A) The anticholinergic effects of tricyclic antidepressants (eg, amitriptyline) can cause dry eye, blurred vision, and triggering of angle-closure glaucoma (ie, ocular pain, headache, unilateral vision loss). Discoloration of vision is not typical.

(Choice B) Important side effects of statins (eg, atorvastatin) include myopathy and hepatic toxicity. Statins may have a small effect on the risk of cataract but otherwise have few ocular manifestations.

(Choice C) Sodium-glucose cotransporter 2 inhibitors (eg, canagliflozin) induce increased renal excretion of glucose and water. Most of the side effects (eg, hypotension, urinary tract infection) are related to glucosuria and fluid shifts; visual symptoms are not common.

(Choice D) Metformin most commonly causes gastrointestinal side effects (eg, nausea, diarrhea). Lactic acidosis is a potentially serious but rare complication. Visual side effects are not a significant concern.

(Choice E) Side effects of ACE inhibitors (eg, ramipril) are primarily related to renal function (eg, hyperkalemia, acute kidney injury) or blood pressure (eg, dizziness, hypotension). Patients may also develop a dry cough due to an increase in circulating bradykinin.

Educational objective:
Phosphodiesterase 5 inhibitors (eg, sildenafil, tadalafil) can cause a transient bluish discoloration to vision. Less common ocular effects include sudden monocular vision loss due to nonarteritic anterior ischemic optic neuropathy; findings include an afferent pupillary defect, decreased visual acuity, and optic disc edema.

References

- Acute nonarteritic anterior ischemic optic neuropathy and exposure to phosphodiesterase type 5 inhibitors.

Pharmacology	Ophthalmology	Phosphodiesterase inhibitors
Subject	System	Topic

Copyright © UWorld. All rights reserved.

A 43-year-old man comes to the emergency department due to painless, progressive visual impairment. The patient was diagnosed with sexually acquired HIV infection 4 years ago. He was previously started on antiretroviral therapy but has been noncompliant with his prescribed medications. His most recent CD4 count was 37 cells/mm^3. Physical examination shows no skin rash or corneal lesions. Funduscopy reveals the findings seen in the image below.

Which of the following medications is the best initial therapy for this patient?

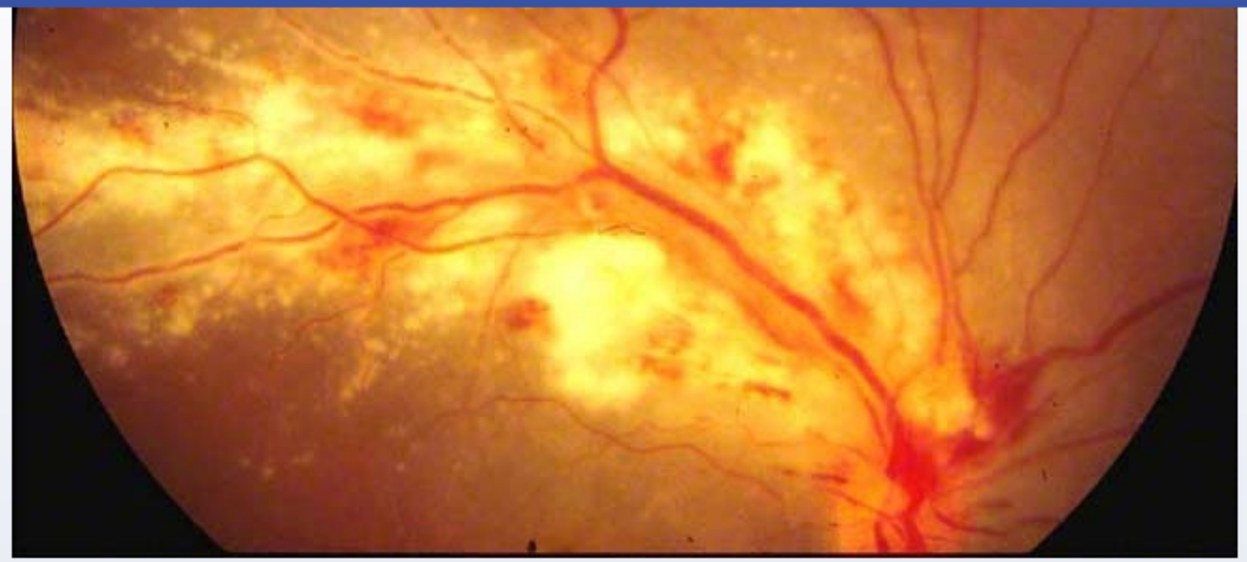

Which of the following medications is the best initial therapy for this patient?

- A. Acyclovir
- B. Amphotericin B
- C. Clarithromycin
- D. Flucytosine
- E. Ganciclovir
- F. Penicillin G

Submit

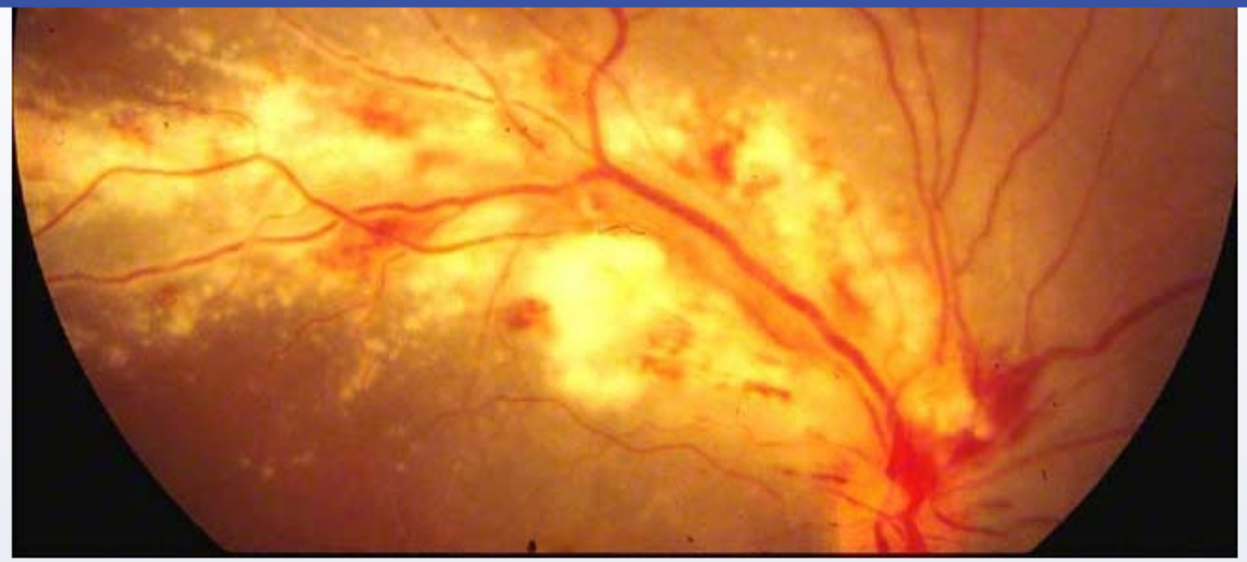

Which of the following medications is the best initial therapy for this patient?

- A. Acyclovir (10%)
- B. Amphotericin B (6%)
- C. Clarithromycin (3%)
- D. Flucytosine (3%)
- ✓ E. Ganciclovir (74%)
- F. Penicillin G (1%)

Omitted
Correct answer

74%
Answered correctly

05 secs
Time Spent

07/05/2020
Last Updated

Black arrows = retinal hemorrhage; **White arrows** = CMV granular retinal lesions.
©UWorld

Patients with untreated AIDS who have CD4 counts <50/mm^3 are at high risk for **cytomegalovirus (CMV) retinitis**. Suspicion is often raised when a patient with advanced AIDS develops slowly progressive **blurred vision**, scotoma (blind spots), floaters, or photopsia (flashing lights). Although most cases are thought to arise due to hematogenous dissemination of CMV, serum testing for the virus is often (~50%) negative.

Patients with untreated AIDS who have CD4 counts <50/mm^3 are at high risk for **cytomegalovirus (CMV) retinitis**. Suspicion is often raised when a patient with advanced AIDS develops slowly progressive **blurred vision**, scotoma (blind spots), floaters, or photopsia (flashing lights). Although most cases are thought to arise due to hematogenous dissemination of CMV, serum testing for the virus is often (~50%) negative. Therefore, the diagnosis is typically established when funduscopy reveals **yellow-white**, **fluffy retinal lesions** near the retinal vessels associated with **hemorrhage**.

Treatment is required to prevent progression and blindness. **Ganciclovir**, a guanine nucleoside analogue that is structurally similar to acyclovir but expresses greater activity against CMV DNA polymerase, is first-line therapy. Patients are also typically started on antiretroviral therapy to increase CD4 count. A major complication of CMV retinitis is retinal detachment due to the replacement of damaged retina with thin, atrophic scar tissue (which is prone to tear).

(Choice A) Acyclovir is used to treat herpes simplex (HSV) and varicella zoster virus (VZV) infections. Although these infections occasionally cause acute retinal necrosis, most cases arise in older, immunocompetent individuals (not patients with advanced AIDS). In addition, HSV retinitis and VZV retinitis are usually associated with significant vitreal inflammation, spotty peripheral retinal lesions, and infrequent hemorrhage.

(Choice B) *Candida* endophthalmitis is treated with amphotericin B. Funduscopy usually reveals focal, white, mound-like lesions on the retina. Most cases occur in the setting of an indwelling central venous catheter or total parenteral nutrition.

(Choice C) Clarithromycin is used in conjunction with other antibiotics for the treatment of *Mycobacterium avium* complex infection, which usually causes fever, night sweats, abdominal pain, and diarrhea.

(Choice D) *Cryptococcus neoformans* infections are treated with flucytosine, a fluorinated analog of cytosine, in combination with amphotericin B. Although cryptococcal endophthalmitis can occur in patients with advanced AIDS, it is much less common than CMV retinitis, and patients often have other manifestations of cryptococcal infection such as skin lesions or meningoencephalitis.

(Choice F) Penicillin G is used to treat ocular (and neuro-) syphilis. Ocular syphilis often presents as uveitis but can cause retinitis, which usually appears as ground-glass lesions with significant vitreal inflammation. Most patients also have manifestations of syphilitic meningitis (eg, headache, vomiting).

Educational objective:
Cytomegalovirus retinitis is the most common cause of ocular disease in patients with untreated AIDS who have CD4 counts <50/mm^3. Diagnosis is made by funduscopy, which typically reveals yellow-white, fluffy retinal lesions near the retinal vessels with associated hemorrhage. Treatment

but expresses greater activity against CMV DNA polymerase, is first-line therapy. Patients are also typically started on antiretroviral therapy to increase CD4 count. A major complication of CMV retinitis is retinal detachment due to the replacement of damaged retina with thin, atrophic scar tissue (which is prone to tear).

(Choice A) Acyclovir is used to treat herpes simplex (HSV) and varicella zoster virus (VZV) infections. Although these infections occasionally cause acute retinal necrosis, most cases arise in older, immunocompetent individuals (not patients with advanced AIDS). In addition, HSV retinitis and VZV retinitis are usually associated with significant vitreal inflammation, spotty peripheral retinal lesions, and infrequent hemorrhage.

(Choice B) *Candida* endophthalmitis is treated with amphotericin B. Funduscopy usually reveals focal, white, mound-like lesions on the retina. Most cases occur in the setting of an indwelling central venous catheter or total parenteral nutrition.

(Choice C) Clarithromycin is used in conjunction with other antibiotics for the treatment of *Mycobacterium avium* complex infection, which usually causes fever, night sweats, abdominal pain, and diarrhea.

(Choice D) *Cryptococcus neoformans* infections are treated with flucytosine, a fluorinated analog of cytosine, in combination with amphotericin B. Although cryptococcal endophthalmitis can occur in patients with advanced AIDS, it is much less common than CMV retinitis, and patients often have other manifestations of cryptococcal infection such as skin lesions or meningoencephalitis.

(Choice F) Penicillin G is used to treat ocular (and neuro-) syphilis. Ocular syphilis often presents as uveitis but can cause retinitis, which usually appears as ground-glass lesions with significant vitreal inflammation. Most patients also have manifestations of syphilitic meningitis (eg, headache, vomiting).

Educational objective:
Cytomegalovirus retinitis is the most common cause of ocular disease in patients with untreated AIDS who have CD4 counts <50/mm^3. Diagnosis is made by funduscopy, which typically reveals yellow-white, fluffy retinal lesions near the retinal vessels with associated hemorrhage. Treatment with ganciclovir is required to prevent blindness.

Pharmacology	Ophthalmology	Cytomegalovirus
Subject	System	Topic

Copyright © UWorld. All rights reserved.

A 45-year-old woman comes to the office due to progressive visual difficulty with night driving and reading road signs and fine print. The patient has systemic lupus erythematosus, which is treated with hydroxychloroquine and prednisone. She avoids sun exposure due to photosensitivity and has vitamin D deficiency for which she takes a vitamin D supplement. Examination shows opacities on the posterior side of the lenses in both eyes. Optic discs are normal. Ocular movements are full. The remainder of the examination shows no abnormalities. Which of the following is the most significant contributing factor for the eye findings in this patient?

A. Hydroxychloroquine

B. Lack of sun exposure

C. Prednisone

D. Systemic lupus erythematous

E. Vitamin D deficiency

Submit

A 45-year-old woman comes to the office due to progressive visual difficulty with night driving and reading road signs and fine print. The patient has systemic lupus erythematosus, which is treated with hydroxychloroquine and prednisone. She avoids sun exposure due to photosensitivity and has vitamin D deficiency for which she takes a vitamin D supplement. Examination shows opacities on the posterior side of the lenses in both eyes. Optic discs are normal. Ocular movements are full. The remainder of the examination shows no abnormalities. Which of the following is the most significant contributing factor for the eye findings in this patient?

A. Hydroxychloroquine (35%)

B. Lack of sun exposure (2%)

✓ C. Prednisone (47%)

D. Systemic lupus erythematous (12%)

E. Vitamin D deficiency (1%)

Omitted
Correct answer
C

47%
Answered correctly

02 secs
Time Spent

04/02/2020
Last Updated

Explanation

Cataracts	
Pathogenesis	• Oxidative damage & opacification of the lens
	• Age >60 • Diabetes mellitus

Cataracts	
Pathogenesis	• Oxidative damage & opacification of the lens
Risk factors	• Age >60 • Diabetes mellitus • Chronic sunlight exposure • Tobacco use • Immunosuppression (eg, HIV, corticosteroids)
Clinical features	• Painless, progressive, bilateral vision loss • Difficulty with nighttime driving • Loss of red reflex • Opacified lens
Treatment	• Artificial lens implantation

This patient has bilateral **opacities in the ocular lenses**, findings consistent with cataracts. **Cataracts** can cause **difficulty with reading** and fine visual tasks; patients often see excessive **glare** at night and **halos** around bright lights due to light scattering in the lens. Examination findings include white or gray cloudiness of the lens, decreased visualization of retinal detail, and loss of the red reflex.

Cataracts are generally related to **chronic photooxidative injury**; the prevalence increases with age, and most patients with cataracts first develop symptoms at age >60. However, cataracts can develop earlier in individuals, such as this patient, with exposure to systemic or ophthalmic **glucocorticoids** (eg, prednisone). This may be due to glucocorticoid-induced transcription of genes in the lens epithelial cell that may alter lens homeostasis or increase the susceptibility to oxidative injury. Other causes of premature cataract formation include diabetes mellitus, ocular trauma, and external radiation exposure.

(Choices A and D) The increased risk of premature cataract formation in patients with systemic lupus erythematosus (SLE) is due primarily to chronic/frequent glucocorticoid exposure, not to the disease itself. Patients with SLE are often treated with hydroxychloroquine; long-term use can cause retinopathy, which presents with decreased central visual acuity, photopsia (flashing lights), and central macular degeneration.

Treatment	• Artificial lens implantation

This patient has bilateral **opacities in the ocular lenses**, findings consistent with cataracts. **Cataracts** can cause **difficulty with reading** and fine visual tasks; patients often see excessive **glare** at night and **halos** around bright lights due to light scattering in the lens. Examination findings include white or gray cloudiness of the lens, decreased visualization of retinal detail, and loss of the red reflex.

Cataracts are generally related to **chronic photooxidative injury**; the prevalence increases with age, and most patients with cataracts first develop symptoms at age >60. However, cataracts can develop earlier in individuals, such as this patient, with exposure to systemic or ophthalmic **glucocorticoids** (eg, prednisone). This may be due to glucocorticoid-induced transcription of genes in the lens epithelial cell that may alter lens homeostasis or increase the susceptibility to oxidative injury. Other causes of premature cataract formation include diabetes mellitus, ocular trauma, and external radiation exposure.

(Choices A and D) The increased risk of premature cataract formation in patients with systemic lupus erythematosus (SLE) is due primarily to chronic/frequent glucocorticoid exposure, not to the disease itself. Patients with SLE are often treated with hydroxychloroquine; long-term use can cause retinopathy, which presents with decreased central visual acuity, photopsia (flashing lights), and central macular degeneration.

(Choice B) Excessive, not limited, lifetime sun exposure is associated with an increased risk of cataracts.

(Choice E) Common manifestations of vitamin D deficiency include hypocalcemia, bone pain, and accelerated bone loss. Cataracts are not a major consequence of vitamin D deficiency.

Educational objective:
Cataracts are related primarily to chronic photooxidative injury. Most patients with cataracts first develop symptoms at age >60 but exposure to systemic or ophthalmic glucocorticoids can cause cataracts at an early age. Other causes of premature cataract formation include diabetes mellitus, ocular trauma, and external radiation exposure.

References

- Risk factors for cataracts in systemic lupus erythematosus (SLE).

Pharmacology	Ophthalmology	Corticosteroids
Subject	System	Topic

Treatment	• Artificial lens implantation

Exhibit Display

Normal eyes & white reflex

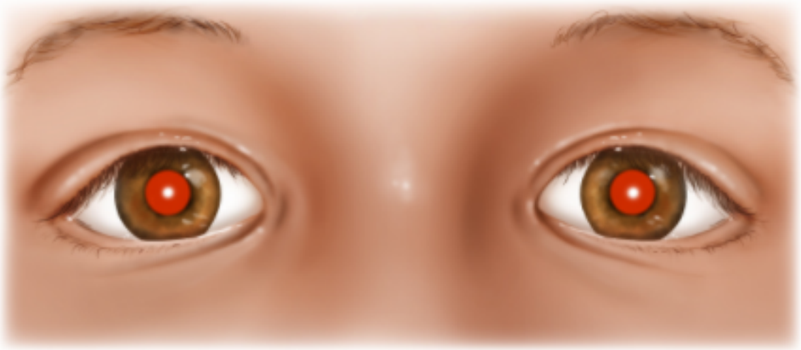

Normal eyes
Red reflexes & corneal light reflexes are equal.

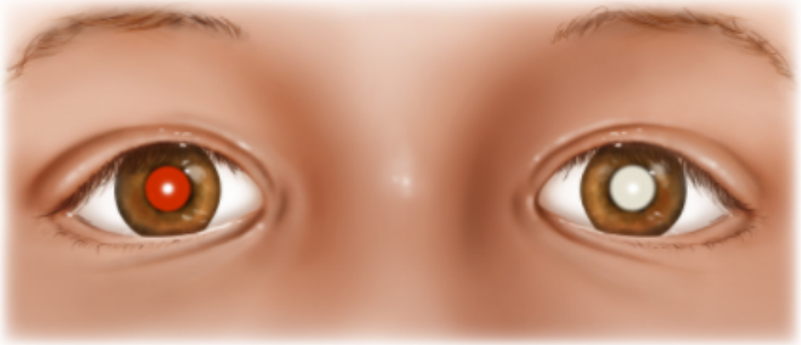

Absent reflex
White reflex on abnormal eye can result from opacities of the lens (eg, cataract) or tumor (eg, retinoblastoma).

©UWorld

Zoom In Zoom Out Reset Add To Flash Card